

Alexei Palarie

Natalia Rusu

**Course of lectures on traumatic injuries in maxilla-facial region in
combat conditions**

Chisinau, 2014

Introduction

In the present study guide for maxilla-facial surgery and dental surgery, briefly, are described some facial and neck diseases namely etiology, pathogenesis, diagnostics, of the clinical progression and treatment of the given diseased peculiarities. Course of study materials on traumatic injuries in maxilla-facial region in combat conditions will help students of dental departments in the given speciality study. The present manual is composed in accordance with syllabus approved for students of dental department, of the State University of Medicine and Pharmacy “Nicolae Testemitanu” of Republic Of Moldova. The manual contains the lecture material for students of 4rd year of stomatological department.

Palarie Alexei - Teaching assistant of the maxilla-facial surgery, implantology and dental therapy department “Gutan Arsenii”, State University of Medicine and Pharmacy “Nicolae Testemitanu” of Republic Of Moldova.

Rusu Natalia – Ph.D., the Head of the Educational Unit of the maxilla-facial surgery, implantology and dental therapy department “Gutan Arsenii”, State University of Medicine and Pharmacy “Nicolae Testemitanu” of Republic Of Moldova.

Topic № 1

GUNSHOT WOUNDS OF THE MAXILLOFACIAL AREA

1. PARTICULARITIES OF THE CLINICAL COURSE AND TREATMENT
OF THE GUNSHOT WOUNDS OF THE FACIAL AND NECK SOFT TISSUE
2. PARTICULARITIES OF THE GUNSHOT FRACTURES OF THE MIDDLE FACIAL AREA
 - Upper jaw fractures
 - Cheekbone complex fractures
3. PARTICULARITIES OF THE GUNSHOT FRACTURES OF THE LOWER JAW
4. COMBINED INJURES
 - Combined radiation injures
 - Combined chemical injures
5. NUTRITION AND CARE OF WOUNDED INTO THE MAXILLO-FACIAL AREA

PARTICULARITIES OF THE CLINICAL COURSE AND TREATMENT OF THE GUNSHOT WOUNDS OF THE FACIAL AND NECK SOFT TISSUE

For a wound of the facial and neck soft wound is characteristic (pic.1.1):

- The presence of the skin and tissue defect as a result of the direct impact of the wounding projectile (bullet, fragment etc.) – *primary wound channel*,
- A given area of the post-traumatic *primary tissue necrosis*;
- At the penetration of the projectile (bullet, fragment) appears a tissue viability breach away from the wound channel – *commotion area or secondary necrosis*,
- The presence of teeth (gangrenously changed or not changed) introduces its particularities into the clinical course (so appears a foreign body as a source of wound infection etc.) and the treatment of a gunshot wound;
- Microbial contamination (both from outside and from the side of oral cavity and nose);
- The presence in the wound of foreign bodies and bone fragments of the facial bones;
- The most frequently penetrating wounds are met (into the oral and nasal cavities, maxillary sinus, eye cavity etc.);
- Often they are combined with the lesion the facial skeleton bones, major salivary glandes, big nerves, vessels;
- Causes expressed deformation;
- The closeness of the vital organs (brain, organs of hearing and vision, upper respiratory tract) causes a great influence on the gravity of the face gunshot wounds and may lead to threatening complications and even to lethal outcome (brain compression and injury, cerebral concussion, subdural hematoma, asphyxia, loss of sight etc.).

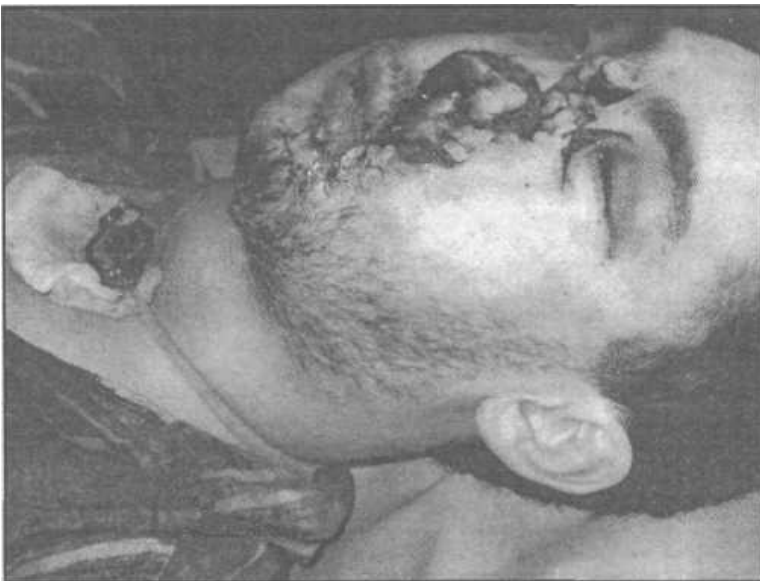The head and the neck constitute approximately 12% of the body's surface, to their side come 15-20% of the battle trauma, but they give 47% of lethality. Although the brain tissue is close to muscle tissue in its density, but its allocation in the brainpan determines an absolutely particular character of wounds in this area with the tissue damage not only on the course of the wound channel by the wounding projectile itself and the bones' fragments, but also from a big distance on account of the effect of "the counter-strike" (B.I.Rudakov, 1984).

Gunshot wounds, depending on the type of the wounding agent, can be: bullet, fragment, from the impact of the blast wave, from the second fragment. According to the morphological particularities all the gunshot wounds and injuries from the impact of cold arms are divided into: contused, point, lacerated,

smashed, cut, chopped, chipped. According to the number of injuries at one wounded: single, multiple, combinative (one wounding agent damages several bodies), combined (at injuries from different agents, for example, a burn and a gunshot wound or from the shock wave and luminous radiation from the nuclear explosion, from fire-origin and from the impact of chemical war gases etc.). According to the length and to the attitude towards the cavities (mouth, nose, maxillary sinus, orbit, cranium cavities): blind, tangent, transverse; non penetrating and penetrating.

The particularities of the clinical course and the treatment of the gunshot wounds of the facial and neck soft tissue

The wounds may be with and without the defect of the tissues. The separation of the wounds in aseptic and bacterial contaminated is conditional, because any wounds, also surgical, contain microorganisms in a bigger or smaller quantity.

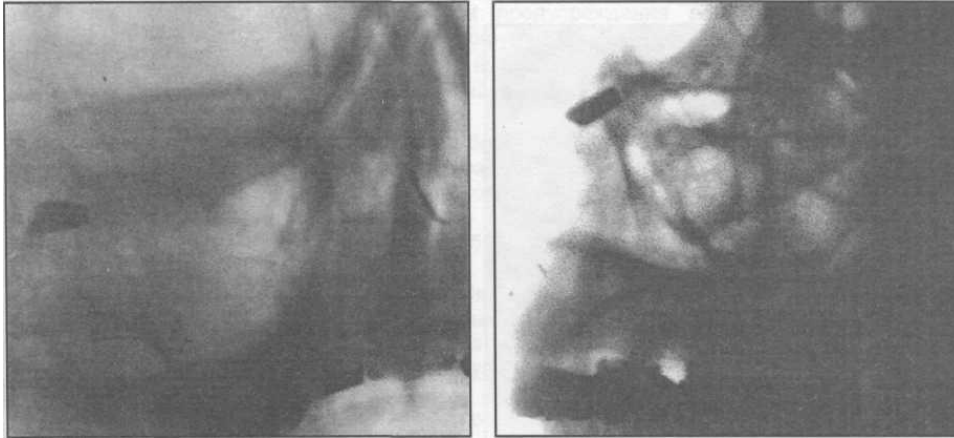

Pic.1.1. The appearance of the patient with a gunshot wound of the maxillofacial area.

The basics of the wound ballistics were laid by N.I. Pirogov. Based on the experience of the military operations on Caucasus he showed that the bullet wounds, which have a low weight and caliber, but fly with a big speed, are as a rule heavier than bullet wounds, which have a smaller speed and a bigger caliber.

In the modern gunshot wounds, which are plotted with high-speed wounding projectiles with an erratic flight, the deviation of the wound channel course grew considerably, its fragmentation has increased, the nonviable tissues area became wider, the area of the hemorrhage has expanded, the formation of closed cavities and pockets, which must be opened during the surgical treatment and, at the end, the area in which the tissues have a reduced viability has increased. Based on these circumstances B.I. Rudakov (1984) thinks it is expedient to distinguish two zones in the gunshot wounds: **zone of the tissues with the complete loss of viability** and with the development of the primary necrosis and **the zone of tissues with a reduced viability** with its possible recovery or with the development of the secondary necrosis and suppurated complications. Such an approach permits, to our mind, to perform more clearly the surgical treatment of the wound, removing only obviously nonviable tissues, hematoma, foreign bodies and bone fragments.

The structure of the wound channel depends to a great extend from the kind of the wounding weapon. By wounding with bullets with a low speed of flight (less than 600-700 m/s) and with a relatively stable nature of the movement, the energy in the tissues is transmitted evenly on the course of the bullet movement and causes tissue injury in the area of the wound channel. The wound channel is usually straight, and by exit wounds the height of the exit hole doesn't exceed the size of the entrance hole too much (pic.1.2.)



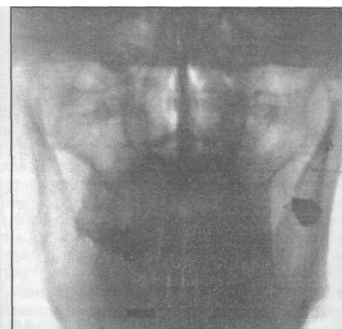(a)

(b)

Pic.1.2. Review (a) and lateral (b) bone roentgenogram of the maxillofacial skeleton of the patient with a bullet wound in the middle face zone.

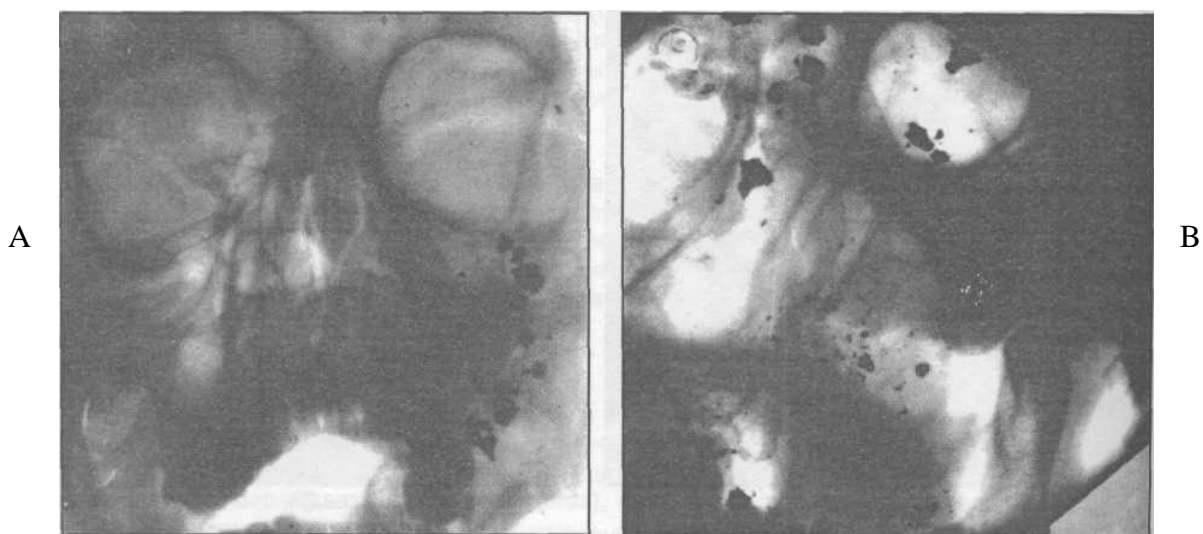
GUNSHOT WOUNDS OF THE MAXILLOFACIAL AREA

By bullet wounds with a high-speed flight (more than 700 m/s) and a low wound resistance during the flight (unstable) there is an expressed deviation of the wound channel, which is characterized by the formation of tissue defects and a big mass of nonviable tissues on the course of the wound channel, by the presence of extensive tissue zone (around the wound course) with a reduced viability. Entrance hole, by exit wounds, is much bigger than the entrance hole. By wounds, which were caused by fragments, which spread in the tissues to all sides from the primary wound channel occur additional defects and tissue injuries. Fragment wounds are usually multiple, more often blind-ended (blind) and have the shape of the cone (the entrance hole is wider than the exit one). But there also may be deviations from the usual fragment wound character, what depends on the initial fragment's speed and its stability in the flight (pic.1.3.).



Pic.1.3. Review roentgenogram of the facial cranium of the patients with fragment gunshot wounds (a).

By wound balls (shots, ball bombs) multiple wounds with small entrance holes are formed, which may be hard to detect, because they may be seated in the folds or in the scalp. By low flight speed the balls, meeting more dense tissues (bones), change the direction of the movement and the wound channel may have the most diverse form (pic.1.4 – 1.5).

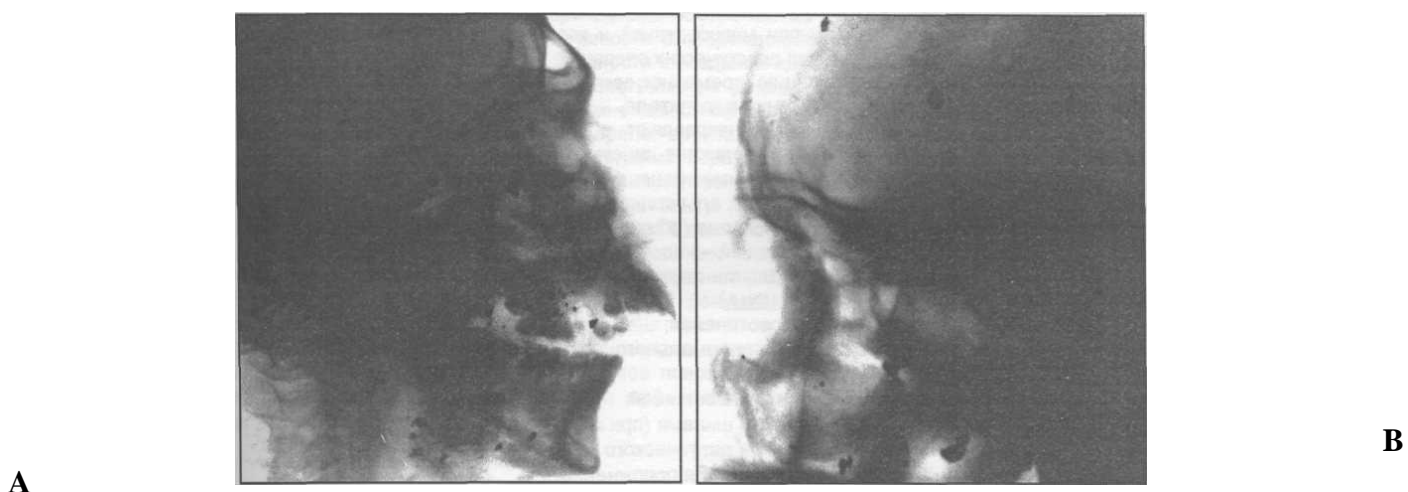


Pic.1.4. Review (a) and lateral (b) bone roentgenogram of the maxilla-facial skeleton of the patient with a gunshot wound.

Particularities of the clinical course and of the treatment of face and neck soft tissue wounds

By high speed of the flight the ball is subjected to deformation already during the flight and the wounds are manifested by the fragment properties. Single balls are met by wounds out of pneumatic guns. Wounds, which were caused by arrow-shaped elements (these elements become stable during the flight), differ in the multiplicity, big penetration, dissipation within the tissue (B.I.Ruakov, 1984).

The injury severity can be different and it depends on the distance, from which the shot was made, on the land (highlands, from the height of a multi-storey building, woodlands and so on), the presence of different obstacles (bushes, tree branches and other) and different means of protection (collective and individual). By shotguns the developing soft tissue swelling worsens significantly the microcirculation and more extensive secondary necrotic tissue changes may appear.



Pic.1.5. Lateral cranium roentgenograms of patients with gunshot wounds (a, b).

Speaking about the treatment of gunshot soft tissue wounds we should remind the field-military surgery doctrine, which is based on the following positions:

- All the gunshot wounds are primary bacterially contaminated;
- The single secure way of prevention of the development of the wound infection is the possibly earlier surgical debridement of the wound;
- The majority of the injured need an early debridement of the wound;
- Prognosis of the course and the outcome of the injures is the best, if the wound was debrided at early terms;
- The volume of the medical aids, the choice of the medical measures and the order of evacuation depend not only on purely surgical indications, but they are determined mostly from the military and medical situation.

In the system of the staging treatment of the patients are distinguished: the first aid (it is provided at the place of the injury), pre-medical, the first medical, qualified and specialized medical aid. The patient gets the first aid at the place of the injury or somewhere nearby. It is provided as self- and mutual aid. This is combating the bleeding, asphyxia, shock. The first medical aid lies in the leading of urgent measures, which are directed to the combating of bleeding, asphyxia, shock. A preparation of the patients for evacuation is lead. The first medical aid is provided by a doctor of any specialty.

The major role in the reduction of lethality among injured, except the perfection of the surgical aid methods, plays the fast delivery of the injured to the phase qualified and specialized aid (I.G.Shaposhnikov, 1984). At the simultaneous reception of a big number of injured it is necessary to make a sorting, what determines the sequence of providing medical aid. First of all a group of people must be distinguished, which don't need a surgical aid. These patients become the trim of the wounds, it means the skin around the wound is trimmed with alcohol, 3-5% alcoholic solution of iodine and an antiseptic bandage is put on the wound.

At the providing of qualified medical aid a group of injured is distinguished, which will have a surgical debridement of wounds by a dentist with the help of a general surgeon. To this group patients are taken, who need the simplest surgical treatment of the wound and suturing without primary plastic surgery. The qualified medical aid to patients, wounded into the maxillofacial area, include:

- The medical sorting;
- Stop bleeding;
- Asphyxia elimination;
- Prevention and struggle with traumatic shock;
- The surgical treatment of soft tissue wounds and facial cranium bones, to the patients which don't need a plastic surgery, that means with a duration of treatment not more than 10 days;
- Transport immobilization (time fixing of fragments of jaw);
- The preparation of the patient for evacuation into the hospital.

All the transportable patients are sent into the maxillofacial department of the specialized surgical hospitals. The maxillofacial wounds are divided into two groups:

- Slightly injured (with isolated soft tissue wounds without significant defects, with teeth injury, alveolar appendages injury and so on);
- Moderately and heavily injured (extensive injures of the face soft tissues or wounds with the soft tissues' defect – nose, lips and so on);

In the hospitals the maxillofacial surgeons take the following measures (specialized medical aids):

- Final bleeding stop;

- Provision of normal breath to the injured (if it isn't done at the previous steps);
- The surgical treatment of the soft tissue wounds;
- The fixing of jaw fragments with the help of a tire (by jaw fracture);
- The execution of medical and dieting treatment of the wounded;
- The prophylaxis and treatment of developed complications;
- The execution of the plastic surgical intervention;
- The provision of orthopedic and therapeutic dental care.

The patients with combined or combinative lesions after the healing of soft tissues' wounds and jaws (after the consultation of a radiologist or other specialist) are transferred to the therapeutic hospital for the treatment of the radiation sickness to another section according to the presence of one or another pathology.

The particularities of surgical treatment of gunshot wounds of the maxillofacial area's soft tissues consist of the following:

- An economical dissection of the wounds wall is done (for the possibility to examine all the blind channels of the wound);
- After the washing of the wound and the removal of blood clots and loose foreign bodies a wound examination is done and the borders of the damaged tissue are determined, excising the obviously nonviable tissues (gentle tissue excision);
- The wound closure is done by the method of impose of deferred primary and secondary stitches;
- An antiseptic bandage is put on the wound, which protects it from harmful effects of the environment and from getting pyogenic bacteria.

If in peace time the majority of wounds of the soft tissue are closed with the help of the primary stitch, in war time a rejection of the primary stitch is done, and deferred and secondary stitches are made.

The late surgical treatment of the soft tissues is made according to the same rules as the early one. But, in some cases, it can reduce to a simple purification of the wound from dirt, fragments of the wounding projectile and to the removal of the necrotic changed tissues. For a good drain of the wound the coves and the pockets, hematomas and abscesses are opened and emptied. The time, after which expiration, the surgical debridement of the wound from the early goes to a late one, is a relative factor. One must take into consideration the clinical symptomatology of the early process, and not the time, which has passed from the moment of the injury causing. The tasks of the primary and secondary surgical treatment of the soft tissues are almost the same. By the primary surgical treatment of the gunshot wounds a big attention is paid to the usage of the early skin plastic as a measure, which is directed towards the prevention of the development of a wound infection and towards the contributing to the wound healing with a good cosmetic and functional effect.

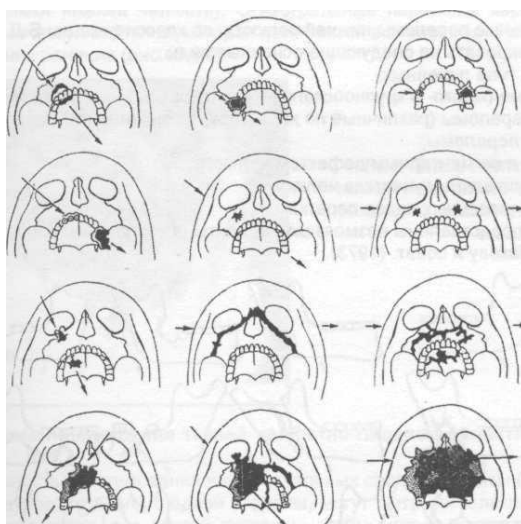
Topic № 2

PARTICULARITIES OF THE GUNSHOT FRACTURES OF THE MIDDLE FACIAL AREA

Upper jaw fractures

Gunshot fractures of the upper jaw are often combined with the damage of other face bones. Due to the immobile connection of the upper-jaw bones with the bones of the cerebral cranium, and besides the closeness of the brain, the eyeball, hearing organs and of the smelling, the clinical symptomatology of these fractures is characterized not only by the diversity, but also by the difficulty of the duration of the injury. A variety of combinations of the gunshot fractures of the upper jaw are met with the injury of other face bones and organs. That is why there appear considerable difficulties in the creation of a common classification of the upper-jaw fractures. By the gunshot injury the bullet (fragment) penetrates through the soft tissues, damages the wall of the upper-jaw bone and it can exit through the upper-jaw sinus, orbit, ORL-organs and to other directions. Having analyzed the gunshot fractures of the upper jaw in dependence of the direction of the wound channel, I.M.Zbarzh (1945) proposed to distinguish some of the most frequently met variants of the injury of this jaw (pic. 2.1). The classification of the gunshot upper-jaw fractures is presented in the 17th chapter of the present instruction book.

The clinical symptomatology of the gunshot fracture of the given area differentiates with a variety of cases. The severity of injury (usually severe or extremely severe), the state of consciousness, the presence of combined injuries and traumatic brain injury (contusion, bruise, and compression), and the presence of signs of liquorrhea (nasal and ear) are estimated. By the physical inspection of the patient the presence of the syndrome of the upper orbital fissure or (and) the cheekbone syndrome is identified, and besides the characteristic symptoms of upper jaw bone injury (stage, glasses symptom, Guerin, Malevich and so on), if there are soft tissue or bone defects, breach of the bite.



Pic. 2.1. Possible variants of gunshot fractures of the upper jaw and the directions of the wound channels (by I.M. Zbarzh).

Examining the oral cavity the state (injury) of the hard and soft roofs of the mouth, the mobility of the alveolar outgrowth, of the teeth and other symptoms are determined. The most difficulties for the diagnosis represent the combined wounds. The difficulties appear in the determination of the back sections of the nose and the deep sections of the pharynx.

An X-ray examination is done, which allows in some cases to clarify the diagnostics and the localization of the foreign body (bullet, fragment) by blind wounds.

The can be met injured with wounds of the both jaws. The diagnostics of such injuries aren't usually complicated. Mistakes, in such a case, appear in the direction of the course of the wound channel (additional channels, not determined outlets because of its small size and so on), and also in the determination of the localization's place of the foreign bodies (bone and teeth fragments).

Cheekbone complex wounds

Cheekbone complex wounds, according to their clinic picture, may be attributed to the number of serious injuries. The cheekbone is firmly connected with the upper jaw, forehead and temporal bones. Cheekbone arch is the anatomical formation, which represents a connection of outgrowths of the temporal and cheekbone. All there bone outgrowths and the cheekbone are firmly connected between themselves into the cheekbone complex. By gunshot wounds all the bones of this complex are injured at the same time.

Cheekbone and arch injuries are rarely isolated and are often combined with injuries of upper jaw, orbit, chewing muscles, facial and trigeminal nerves, ear, nose bone and so on. Taking into consideration the closeness of the cheekbone complex with the cranium and its firm connection with the adjacent bones such injures are accompanied by brain injuries (commotions, bruises and compression of the brain).

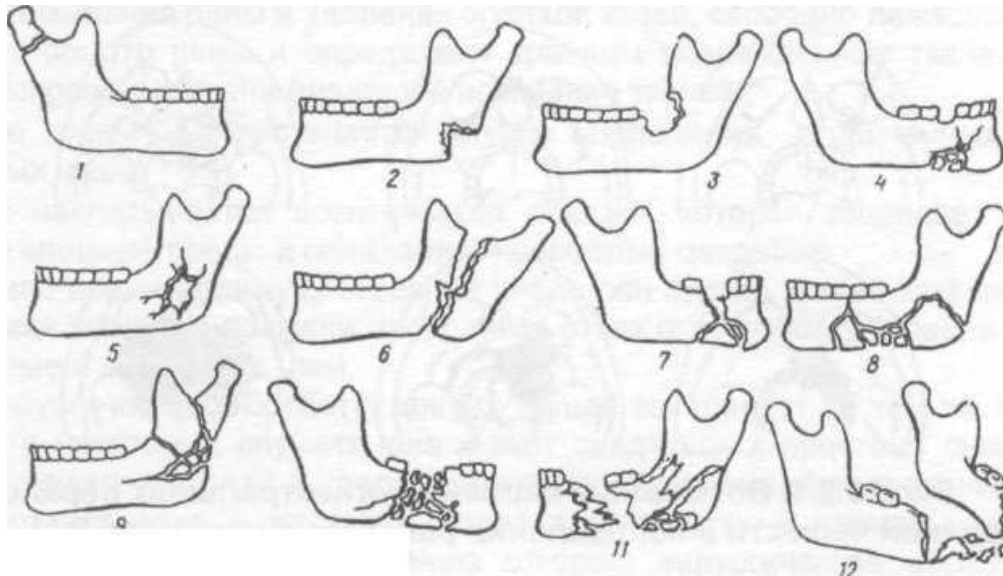
By gunshot fractures of the cheekbone and arch there can be combinations of clinical symptoms of these two injuries (restriction by opening the mouth, the stage symptom, upper lip numbness, discharge of blood from the nose and so on). By combinative injuries (with the upper jaw fractures) the clinical symptomatology is spread (the orbit injury – exophthalmos and the syndrome of the upper orbital gap, diplopia, decreasing of the sight etc.). The clinical picture is determined by the degree of the bone and soft tissues injury. For the precision of the bone changes and that of the fragment or foreign bodies' presence (bullet) an X-ray is done.

PARTICULARITIES OF THE GUNSHOT FRACTURES OF THE LOWER JAW

All the lower jaw gunshot fractures, according to the classification made by B.D.Kabakov and co-authors (1973), may be grouped into the following types:

- Fractures of the linear type;
- Comminuted (small and big comminuted) with the breach of the jaw continuation;
- Marginal fractures (different at character) with the maintenance of the continuity of the jaw
- Perforated fractures;
- Fractures with a segmental jaw defect;
- The breakaway of large parts of the jaw;
- Combination of the named fracture types.

In the pic.2.2. the possible variants of the gunshot injuries of the lower jaw are presented, according to B.D.Kabakov and co-authors (1973).



Pic. 2.2. The possible variants of the gunshot injuries of the lower jaw (by B.D. Kabakov). 1 – linear fracture at the base of the base condyle; 2,3,4, - edge fractures; 5 – perforated fracture; 6 – longitudinal fracture of the branch; 7,8,9 – coarsely comminuted fractures; 10,11 – fractures with the bone defect; 12 – shooting of the chin.

The gravity of the patient’s injury depends not only on the type of the lower jaw fracture, but also on the character (penetrating and not penetrating) and on the degree of the injury of the encircling soft tissues and jaw-facial area bodies (sight, audition etc.), on the complications of the wound healing, and besides on the promptitude and usefulness of the provision of the medical aid to the patient.

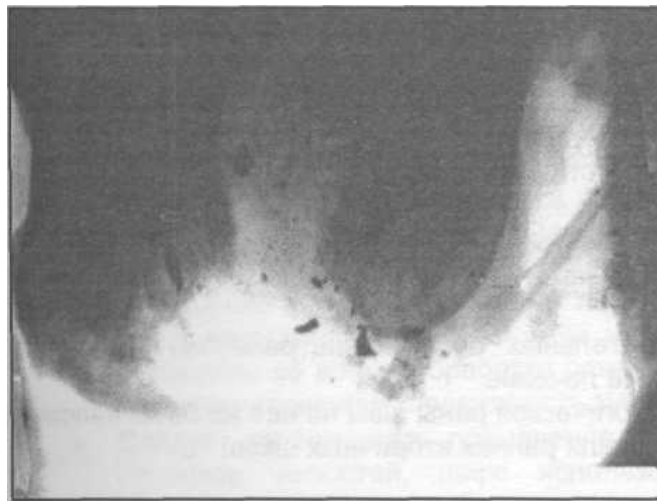
A great variety and changeability of the clinical picture are a peculiarity of the gunshot injuries of the lower jaw.

The clinical symptomatology of the gunshot injuries changes in dependence with the time, which had elapsed from the moment of getting the wound. The aspect of such patients is typical: the mouth is half-open, there is a soft tissue injury (with or without a tissue defect); blood and saliva runs out of the mouth; a confused and helpless facial expression; hanging and moving skin and muscle flaps enhance the disfigurement; bare areas of the mouth, tongue, neck with a marked hemorrhage are seen. The chewing, swallowing, speaking and breathing are disturbed. By bilateral fractures of the lower jaw, which are accompanied by the injury of the soft tissues bottom of the mouth and tongue, the patients take enforced position (the face is turned down, lying on the abdomen), because of the appearance of the dislocation asphyxia.

In several hours after the injury the edema of the surrounding soft tissues grows, and after 1-2 days the wounds is infected (it covers with necrotic plaque etc.), the general condition of the patient get much worse (the temperature of the body rises, chill, the impossibility to swallow etc.).

At the receipt of the victim the first thing to do is the assessing of his general condition, the degree of blood loss, the severity and the type of the respiratory insufficiency. In consequence of blood loss a hemorrhagic collapse or a shock may develop (look at the par. “Complications by soft tissue injuries”). On the ground of clinical symptoms the presence of this complication is determined. By combinative craniofacial trauma the state of consciousness and the degree of the injury severity (look at the par. “Combinative craniofacial trauma”), the development of the traumatic illness is determined. Afterwards a visual inspection of the craniofacial injury is made, the change of the bite is determined and then an oral

cavity inspection is made. For the determination of the fracture characteristic an X-ray examination is made (review and side X-ray images of the lower jaw). Gunshot fractures are characterized by the most diverse clinical picture, which changes in dependence from the period of time, which elapsed from the moment of getting the injury (pic.2.3).



Pic. 2.3. The X-ray image of the lower jaw of the patient with a gunshot injury (a defect of the bone tissue is there).

Gunshot injuries of the maxillofacial area have the following particularities:

- The impossibility to use the individual means of protection (gas mask);
- The presence of teeth, which from the one side may be “fragments”, which infect the surrounding tissues, but from the other side the teeth can be used for the fixation of fragments by the treatment of fractures;
- The cosmetic face disfigurement, what must be taken into consideration while doing the gentle debridement of the wound;
- A good vascularization and an abundant innervation of the maxillofacial area, what contributes from the one side to the faster healing of the wound, and from the other side the wounds are accompanied by heavy bleeding, intense pain etc.
- Closeness of the upper respiratory tract contributes to the appearance of asphyxia or respiratory insufficiency;
- Closeness of the brain causes the development of a combinative craniofacial trauma;
- The particularities of the treatment and nutrition of the maxillofacial patients.

The surgical debridement of extensive soft tissue and facial skeleton wounds must be made under general anesthesia (endotracheal or intravenous narcosis). By surgical debridement of gunshot wounds following measurements must be respected:

- The wound dissection of the soft tissues must be moderate;
- Tissue excision must be gentle (only nonviable and smashed tissues are excited);
- A final stop of bleeding vessels is done;
- The removal from the wound of blood clots, of soft tissue fragments, foreign bodies and freely lying bone fragments (only big bone fragment are left, which maintained the connection with the soft tissues);

- Sparing resection of protruding sharp bone edges and the coating of fragments with soft tissue;
- By injury of alveolar jaw appendages the destroyed teeth and the teeth which are in the tooth gap must be removed;
- By revision of the injured upper-jaw bone the attention is paid to the presence of the communication with the upper-jaw sinus; foreign bodies, bone fragments, injured areas of the mucosa, blood slots are removed from it;
- By jaw complex bone injury they must be set, so that in the future no facial skeleton deformations appear.
- The nose bones are repositioned and fixed in the right position with the help of conformal iodine swabs;
- By displacement (lowering) of the eyeball it is lifted up and maintained with the help of a conformal iodine swab, which is introduced in the upper-jaw sinus and withdrawn through the rhinostoma;
- By injury of the parotid gland or its main excretory duct it is necessary to sew the large salivary gland capsule and to restore the integrity of the excretory duct, if it doesn't work out, there is necessary to create a false duct (internal salivary fistula);
- A revision of the injured channel is made with the purpose of identifying the hidden "pocket" with the revision of the last;
- There is a necessity to eliminate the communication between the oral cavity and the maxillary sinus, between the oral cavity and the nose cavity, also to isolate the outer wound from the oral cavity (to provide a local plastic if necessary);
- By big perforating soft tissue defects the edges of the skin must be sewn to the oral cavity mucosa, this means to make a so called wound lacing;
- The fixation of the jaw fragments with tooth tires is done (look at par. 18.4. of the given instruction book);
- For the prophylaxis of the inflammatory complications development the patient is given an antibacterial and fortifying treatment.

If for some reason after the surgical wound the sutures were not put on it, it is necessary to resort to the putting of deferred or early secondary sutures.

Topic № 3

COMBINED INJURES

To combined injuries refer all the injuries, which appear by the impact on the body of two or more striking factors (shock wave and luminous radiation, gunshot wounds with the impact of chemical war gases etc.).

All the combined injuries, regardless of their origin, have several common features:

- Syndrome of reciprocal complication (the presence of the one type of injury aggravates the course of the other and vice versa);
- Not only the first medical aid gets more complicated, but also the whole process of the following treatment;
- There are often poor functional results of the treatment.

In association with the combined injuries it is necessary to remind about such concepts like degasification and decontamination.

Degasification – neutralization and (or) removal of the toxic substances from the surface or from the volume of the infected objects, done with the purpose of preventing destruction to people.

Decontamination – is the removal of radioactive substances from the surface or from the volume of the contaminated objects, which is led with the purpose of radiation injuries prevention.

Combined radiation injures

The effects of radiation injury on the course of a gunshot wound develop on the following way:

- The reparative processes in the wound slow down and get subverted;
- The development of infectious complications of local (wound suppuration) and general (sepsis) character becomes more frequent;
- The duration of the latent period of the radiation disease decreases;
- The gravity of the radiation injury increases;
- Threshold of the radiation sickness development against the background of a severe gunshot wound decreases.

By combined radiation injuries the primary surgical debridement of the wound should be done at possibly early terms. The primary surgical debridement of the wound ends with the overlay of a primary suture or conduct of the skin plate. A special role belongs to prophylaxis of the wound infection development; this means the healing takes place under the guise of antibiotic therapy. The syndrome of reciprocal burdening is more clearly manifested in the midst of the radiation disease. That is why there appears the main rule of wound treatment by combined radiation injures – it is necessary to use the hidden period of the radiation disease to perform the surgical measurements (primary surgical debridement of the wound, primary skin plastic, reconstructive surgery).

V.V, Fialkovsky (1966) proposes a scheme of the surgical debridement of combined radiation injuries of the maxillofacial area:

- The surgical debridement should be done at early terms, in the first 24 hours after the injury if possible, better not later than in 48 hours.
- The debridement must be momentary, exhaustive and it must end with the fixation of jaw fragments (if there is a necessity), imposition of primary sutures on the soft tissue wound, local and intravenous antibiotic.
- General principles of the surgical debridement of the maxillofacial area wounds are preserved also by combined injuries. The revision of the wound must be done thoroughly, besides for the stop of

bleeding in the wound should be used not the usual ligation of vessels, but if possible the sewing of bleeding vessels with soft tissues.

- Taking into consideration that the mucosa or skin wounds which were not sewn during the debridement, may turn into big infected necrotic ulcers in the midst of the radiation disease, that why one must aim in any case to close the wound with the simple convergence of the edges or by means of cutting out and moving the flap from the nearby tissues.
- Foreign bodies, also metallic ones, are eliminated according to general indications. Metallic prosthesis, inlays and other constructions in the oral cavity may be left during the patient's debridement, if there are no direct indications for their elimination for other reasons (tooth mobility under the crown in the fracture area etc.).
- The use of tooth metal tires for the fixation of jaw fragments should be limited; there must be wider used operational methods of immobilization of bone fragments, especially by large doses of radiation.
- The surgical debridement of the wounds, which were occasionally infected by radioactive substances, is done by rules, which were adopted in the maxillofacial surgery, but more radically. Metallic foreign bodies, which lie next to the wounded surface, are possibly to be removed, because they can carry on them radioactive particles.
- At presence of blind pockets and courses, the last should be split for the removal of foreign bodies, teeth and bone fragments, and also for cleaning and aeration of the wound.
- The edges of the wound are brought together, and the intervals are plugged loosely with gauze and are closed with aseptic bandage. These swabs should be changed daily. Later, if the clinical course is favorable, such wounds may be closed by means of a secondary suture.

In the midst of the radiation disease some bleeding and wound sepsis appears different processes in the maxillofacial area join (gingivitis, stomatitis, petechial and drain hemorrhages under the mucosa, ulcerative-necrotic lesions of gums or tonsils etc.). In this period even a drastically made surgical debridement of the wound and the active antibacterial therapy don't usually bring success.

Combined chemical injures

The maxillofacial wounds may be struck by poisoning substances of two types: a) those which have a local and those which have a general effect; b) those which have a general resorptive effect. **The local effect** of the poisoning substances lies in the development of a marked inflammatory-necrotic process, besides in the more or less important deceleration of the wound cleaning processes and reparatory processes. A severe disturbance of trophic tissue and a decrease of the overall resistance of the organism highly contribute to the development of infectious complications' development. Along with the local effect, which several poisoning substances have, the most typical by wound infection is their general resorptive effect. The character of **the general resorptive effect** is determined by the particularities of the composition of the used CWF. The absorption of the poisoning substances through the wounded surface takes place quicker, than through the skin. In connection with it by defeat of PS the minimal killing dose reduces significantly.

By **mustard gas poisoning** the wound has a specific odor of burnt rubber or mustard. Sometimes in the wound black oil spots of mustard gas can be seen. In the coming hours after the injury the swelling of its edges is detected. At the end of the day there are bubbles on the congested skin around the wound. And the wound covers with necrotic membrane. In the future the tissue necrosis progresses, an infection develops, and the clearing and wound healing processes are delayed for a long time. The symptoms of the general resorptive effect of the poisoning substances are determined shortly after the injury and express themselves in the general retardation of the patient, loss of appetite, nausea, vomiting, headache, dizziness. In more

severe cases there are convulsions and comatose state, not rare with lethal outcome (A.A. Vishnevsky, M.I. Shreder, 1975).

By **poisoning with lewisite** the wound smells like geraniums. In the moment of contamination the injured feels a sharp ache, which isn't usual for a trauma. In the first minutes after the contamination the wound tissues get gray color, which is followed by yellowish-brown color. Shortly afterwards around the injury pronounced effects of inflammation will develop, and after 6-8 hours petechial hemorrhages appear in the skin surrounding the wound. At the end of the day bubbles will appear here, which will gradually merge, and by massive contamination the wound edges will get pale yellow color (lifetime fixation of tissues). A high wound bleeding is observed. The bleeding sometimes takes threatening character. In 3-4 days after the injury the wound surface will cover with dry necrotic membrane. Soon an infection will develop. By the contamination of wounds with lewisite the effects of intoxication are seen earlier and they are more pronounced than at mustard gas poisoning. To the number of the typical symptoms of the intoxication refer: weakness, dyspnea, pulmonary edema, collapse (A.A. Vishnevsky, M.I. Shreder, 1975).

By **phosphorus poisoning** the wound has a specific odor, which is similar to garlic, and the skin around it is burnt. The injured tissues are covered with grey crust, they are smoking. Sometimes the clothes or bandage inflames. Later a sera-purulent discharge from the wound appears. As a result of the general resorptive effect jaundice appears in the following 2-3 days, there appear bleedings in the intestines and urinary tracts, bleedings into the skin and mucosa. Subsequently on the first plan come the effects of the hepatic failure, which can lead to the development of coma with a lethal outcome in the next hours after the injury.

Primary surgical debridement of the wound is one only after the medical relief action of poisoning substances. There are antidotes for some poisoning substances (tab.4.1).

The wound toilet of the maxillofacial area goes together with its **degasification**. By **mustard gas poisoning** the surrounding skin is debrided with 10% solution of chlorine bleach, and the wound with 2% aqueous solution of chloramine. By **lewisite poisoning** the wound is debrided with 5 % solution iodine, and the wound with aqueous solution of Lugol.

By primary surgical debridement of the wound all the foreign bodies and bone fragments must be removed. A careful hemostasis is done. During the operation the wound is periodically washed with 2% aqueous solution of chloramine for the removal of wound detritus and its degasification. The wound is plugged loosely with gauze swabs, which are wetted in a 2% aqueous solution of chloramine. Afterwards on the wound are imposed a delayed primary and early secondary sutures.

The infected bandaging material is folded in geometric receivers and afterwards it is burnt. The decontamination of instruments is done through the way of its careful wiping with cotton, which is wetted with petrol, and it is boiled after it during 25-30 minutes in 2% bicarbonate of soda solution. The infected gloves are mechanically cleaned with soaped water, and after it they are drown for 20 minutes in a 5% solution of chloramine and in conclusion they are boiled (in normal water) during 15-20 minutes.

Table 3.1

Antidote means, which are used by acute poisoning (N.I.Bortshuk, 1998)

Antidotes, form, methods of application	Toxic substances
Alloximum lyophilized – ampules of 75 mg, intramuscularly	OPs
Amyl nitrite (propyl nitrite) – ampules of 0,5 ml for enhance	Hydrocyanic acid, cyanides
Anti-cyan – ampules of 1 ml of 20% solution intravenously, 0,75 ml intramuscularly	Hydrocyanic acid, cyanides
Atropine sulfate – ampules of 1 ml of 0,1% solution, intramuscularly, intravenously	OPs

Dicaptolum – ampules of 1 ml, intramuscularly	Hydrogen arsenide, OMC
Trimedoxime bromide – ampules of 5 ml of 10% solution, intramuscularly	OPs
Diaethyimum –ampules of 5ml of 10% solution, intramuscularly	OPs
Cobalt edetate – ampules of 20 ml of 1,5% solution, intramuscularly slowly in drops	Hydrocyanic acid, cyanides
Izonitrozinum – ampules of 3 ml of 40% solution, intramuscularly	OPs
Calcium chloride – ampules of 10 ml of 10 % solution, intramuscularly	Oxalic hydrofluoric acid
Oxygen (inhalation)	Carbon monoxide, hydrogen sulfide etc.
Magnesium oxide – 20-40 mg in 1 liter of water (gastric lavage)	Inorganic acids
Methylene blue – ampules of 20 ml or flacons of 50-100 ml of 1% solution in 25% solution of glucose (“Chromosmon”), intravenously	Hydrocyanic acid, cyanides, aniline, nitrobenzene
Sodium nitrite – ampules of 10-20 ml of 2% solution, intramuscularly in drops	Hydrocyanic acid, cyanides
Sodium thiosulfate – ampules of 10-20 ml of 2% solution, intravenously	Ferrihemoglobin formers, Hydrocyanic acid, cyanides, mercury, arsenium compounds
Pyridoxine hydrochloride – ampules of 3-5 ml of 5% solution, intravenously, intramuscularly	Hydrazine
Succimerum – flacons of 300 ml, intramuscularly	Mercury
Tetacinum-calcium – ampules of 20 ml of 10% solution, intravenously in drops in 5% solution of glucose	OMC, arsenium, dichloroethane
Activated carbon (suspension of 20-30 g in water in or for gastric lavage)	By all enteral contaminations
Unithiolum – ampules of 5 ml of 5% solution (1 ml for 10 kg of body weight), intramuscularly	Arsenium, mercury, other heavy metals
Ethanol – 30 % solution inside for 50-100 ml, intravenously (1 ml for 10 kg of body weight per 24 hours in 5% solution)	Methyl alcohol, ethylene glycol

Topic № 4

NUTRITION AND CARE OF WOUNDED INTO THE MAXILLO-FACIAL AREA

Any gunshot injuries in the face cause one or other disorders in the normal ingestion. The severity degree of these breaches changes in dependence with injury character, localization and severity of anatomic injuries (with difficulty in chewing and nibble of solid food to the full breach of receiving any food). Injured with transverse defects of soft tissues of the perioral area lose a great quantity of liquid with the leaking saliva (up to 2-3 liters a day). If they aren't provided at time with its replenishment body dehydration will appear. By impossibility of adequate nutrition of the injured nutritional depletion develops. At the stage of qualified medical aid the maxillofacial wounded must be given to drink and to eat.

The food for the injured must be physiologically complete and balanced by its chemical composition; this means that it must contain all the necessary components for life support with compulsory registration of his daily energy loss. For maxillofacial injured the food must include mechanical (pulverized, homogenized etc.) and chemically sparing properties (it mustn't irritate the wound, the food temperature must be from 45° till 50°C, it mustn't increase the secretion of the salivary glands). The injured with maxillofacial traumas must be given three physiologically complete diets (look at their description in the par. "Reparative osteogenesis", chapter № 18):

- First jaw table (probe);
- Second jaw table (mushy);
- General table (№ 15).

At the stage of patient's evacuation the nutrition is done due to dietary food concentrates, which are diluted with boiling water and after their cooling till 50°C the nutrition from food concentrates is ready for use.

First jaw table is assigned to the injured person with the lost chewing and swallowing functions. The food is introduced into the injured with the help of the probe. **Second jaw table** is assigned to the injured people, who have completely lost the swallowing and sucking function. **General table** is assigned to the recovering patients, who can chew the food.

The nutrition of maxillofacial injured is an answerable and laborious procedure. All the means of feeding the injured can be classified into two groups: enteral and parenteral. Enteral nutrition is done orally, with the help of a probe (stomach or duodenal) or in the form of nutrient enemas (rectal). The majority of the maxillofacial injured must be fed in the natural way, it means through the mouth (orally). It is done with the help of a spoon, cup or feeding cup. The oral nutrition is the most physiological one. During the nutrition the injured may sit on a chair or lay in the bed (depending on the severity of the general state). By jaw fragments' immobilization with tooth tires the mouth opening becomes impossible. In this case the food is introduced into the oral cavity through the retro molar space or through the given defect in the dentition. In the first days after the injury the nutrition is done with the presence of nursing staff, afterwards it is done by the patient alone.

The probe nutrition is used by extensive damages of the anatomical structures of the maxillofacial area. The stomach probe, lubricated with glycerol, is introduced through the nasal passage into the rhinopharynx. After its introduction to 15-17 cm the patient's head is leaned forward and he/she is asked to make a swallowing motion. During these motions the probe is makes its way till the stomach, it means up to 45 cm in depth. The esophagus is situated from the place of probe introduction (nostrils) at the distance of 30-35 cm, and the duodenum – 50-55cm. To check the right location of the probe (especially by people, who are in the state of unconsciousness) a gauze cloth thread is brought to its outer end (hole). By probe finding in the trachea the thread does oscillating moves at patient's respiration, and by probe localization in the

esophagus (stomach) – the thread is unmoved. The probe nutrition is done with the help of a funnel or the syringe Janet. The presence of the probe in the patient mustn't exceed 10-14 days, afterwards it is changed with another one.

Parenteral nutrition is artificial nutrition, by which liquid nutrients (protein preparations, glucose solutions etc.) are introduced into the patient's the bloodstream. For the parenteral nutrition the following means are used: aminosteril, aminosteril KE, aminoplasma, aminosol, infesol-40 and other.

The treatment of the patients injured into the maxillofacial area is usually divided into general and specific (connected with the peculiarity of the face's injury). Some authors consider that there can't be lead a strict bound between them and this division is conditional. I consider that from the methodological point of view this division is quite acceptable.

The general treatment includes the following measures:

- Bed care after the conduct of surgical intervention (during the first days);
- Bed care by injured with combinative traumatic brain injury (according to the neurologist's recommendations);
- For the prophylaxis of bronco-pulmonary complications it is recommended to do breathing exercises 3-4 times per day (it is necessary to do deep breaths);
- For the prophylaxis of decubitus (by seriously ill) the patient should be turned from one side to another several times during 24 hours;
- Prevention of patient's hypothermia by chamber aeration, by drinking cold water etc.

Topic № 5

COMPLICATIONS OF JAW FRACTURES

1. POST-TRAUMATIC OSTEOMYELITIS
2. GUNSHOT JAWS OSTEOMYELITIS
3. VIOLATION OF REPARATIVE REGENERATION OF THE LOWER JAW
4. COMPRESSION SYNDROME
5. OTHER COMPLICATIONS

All post-traumatic complications that may occur to patients with gunshot or other fractures of the jaws can be organized as follows.

The classification of complications of fractures of D.A. Timofeev (1998):

I. Early complications:

- bleeding and bruising;
- suppuration of the bone (post surgery) wounds;
- secondary displacement of bone fragments;
- emphysema of soft tissues;
- inflammatory processes in soft tissues (lymphadenitis, inflammatory infiltrate, abscess or cellulitis, thrombophlebitis of face veins etc.);
- other (displacement of the eyeball, diplopia, etc.).

II. Late complications:

post-traumatic and gunshot osteomyelitis;

- post-traumatic and gunshot sinusitis;
- delayed consolidation of bone fragments;
- ununited fracture of the jaw;
- pseudarthrosis of the lower jaw;
- deformation of the jaws;
- disease of the temporomandibular joint;
- contracture of the lower jaw;
- compression syndrome;
- other (nerve damage, bronchopulmonary complications, brain damage, etc.).

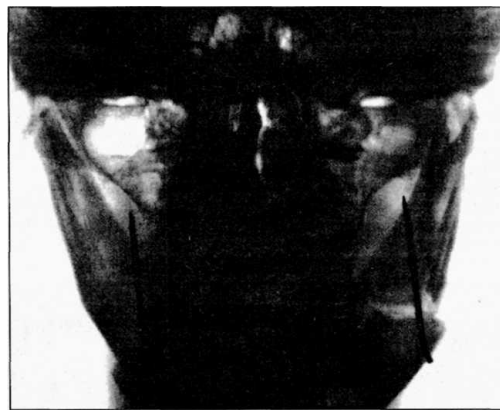
Early post-traumatic complications (hemorrhage, hematoma, abscess, phlegmon, etc.) occur in the first hours or days after injury. These complications are described in some detail in the relevant chapters of this manual. Therefore, we won't dwell on them.

Festering of the bone wounds as a result of fracture of the mandible can be observed in the first 3-7 days after injury. A hematoma infection can arise, which is located between fragments of bone. Hematoma infection usually occurs from a odontogenic foci of chronic infection (periodontitis, periodontitis, gingivitis, pericoronium, etc.). The development of infection in the fracture gap is favored by: poor (low) resistance of the patient body, chronic alcohol intoxication (drug addiction), or chemical intoxication; refusal of the affected of treatment, surgical treatment technique violation, wrong attitude to the tooth while it is in the line of fracture, unstable fixation of bone fragments, etc. At the fracture of the lower jaw there is profuse salivation, and the crack of fracture flow into saliva. This facilitates the penetration of pathogens and the hematoma is infected. It should be noted that the speech and swallowing acts increase the penetration of

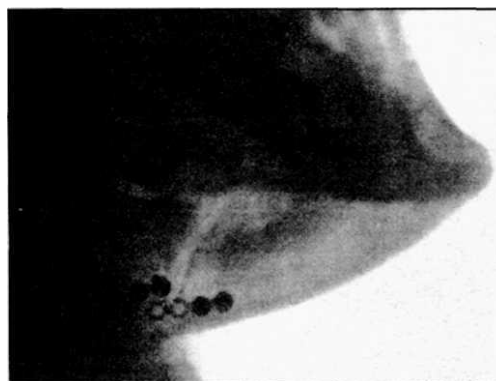saliva into the crack of fracture, and from there into the surrounding soft tissue. It must be remembered that the pathogenic microflora may come into the crack of fracture and through the damaged soft tissue of maxillo - facial area. Suppurative processes in the wound more often occur in the case of localization of the fracture within the tooth row (open fractures) and much less in the case of closed fractures.

Festering of bone wounds as a result of fracture of the maxilla is observed at late fixation of bone fragments. The mobility of the maxillary bone fragments contribute to the "suction" in the bone wound of the oral content through the damaged mucosa. The previously mentioned factors contribute to the bone wound infection.

Secondary displacement of bone fragments can be found both in the conservative treatment of fractures, as well as during fixation. The main reason for the displacement of bone fragments is the lack of fixation of bone fragments to each other, the use of early functional loads, the violation of regimen by the patient (self-removal of intermaxillary traction), the additional trauma, etc. (Pic. 5.1-5.2).



Pic. 5.1 Secondary displacement of the fragments of the mandible after osteosynthesis with Kirchner spokes, caused by the early withdrawal of the maxillary tooth rods and tires. The Kirchner spokes perforated the inner cortical plate of the mandible in the branches and penetrated the soft tissue.



Pic. 5.2 Secondary displacement of fragments of the mandible, caused by a broken titanium miniplate, as a result of an early functional loading.

POST-TRAUMATIC OSEOMYELITIS

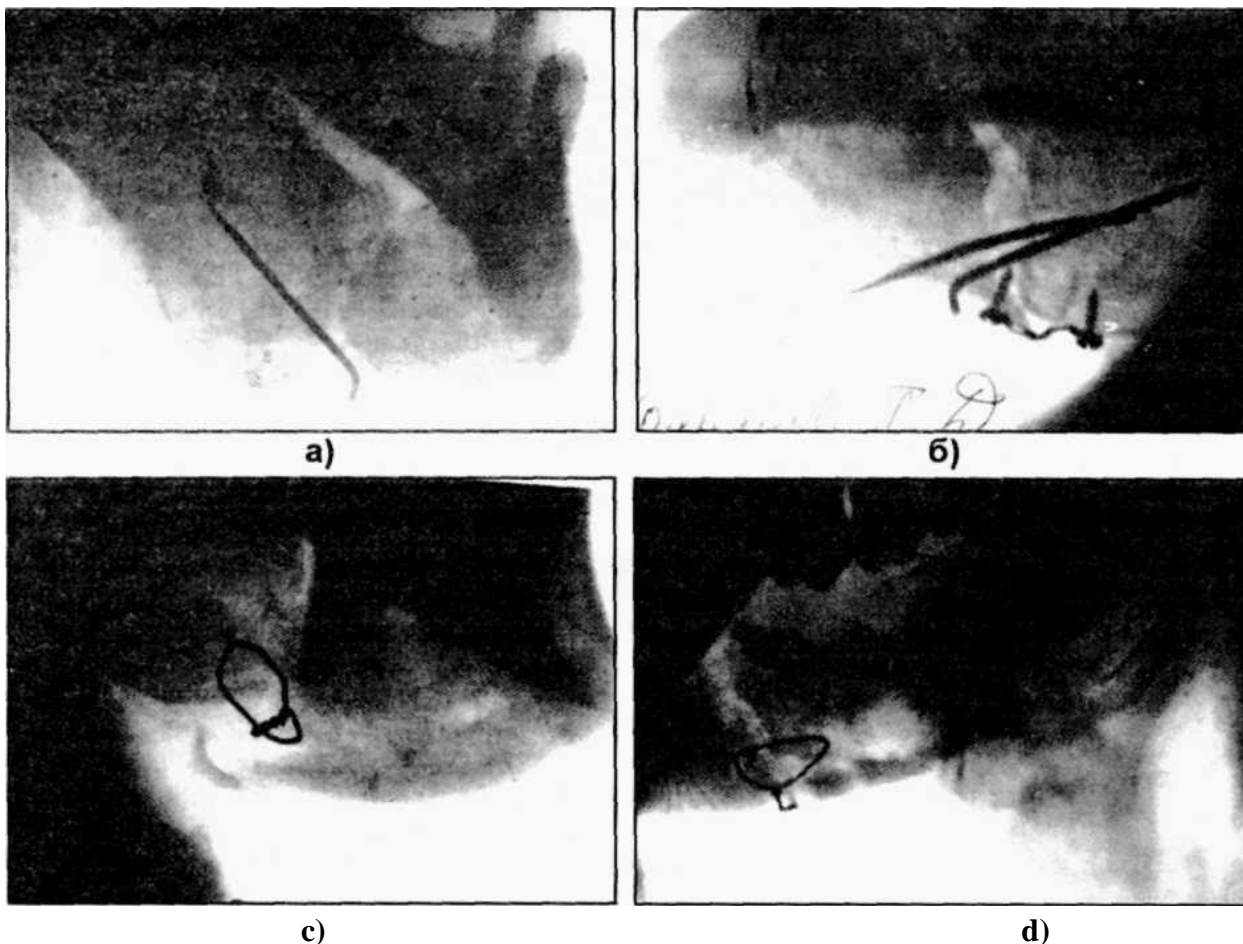
Among the complications of mandibular fractures, post-traumatic osteomyelitis occurs from 9 to 30% (A.I. Nerobeev, 1969; V.A. Malyshev, 1981; B.A. Umbertyarov, 1983; A.A. Timofeev, 1987, 1998, etc.).

So far there is no single coherent theory that could explain the mechanism of post-traumatic osteomyelitis. Nerobeev A. (1969) convincingly demonstrated that the sensitization of the organism significantly contributes to this inflammatory complications. In subsequent years, is established the influence of lesions of the peripheral branches of the mandibular nerve on the healing of fractures of the mandible and the development of post-traumatic complications (S. N. Druzhinin, 1971, 1975; N.F. Cheremnov, 1974; A.G. Shargorodsky, 1975, etc.). Allergic and neurotrophic theories in some extent complement each other and can partially explain the pathogenesis of posttraumatic osteomyelitis at patients with fractures of the jaws. An important role in development of posttraumatic complications are microorganisms that are in odontogenic foci of chronic infection, the mechanical factor as well influences (the presence of bone fragments, the mobility of bone fragments, areas of necrosis, rupture of vessels, etc.)

Our studies have shown that inflammatory complications occur to patients not only with a low overall resistance of the organism, but with reduced local factors of nonspecific resistance (A.A. Timofeev, E.V. Gorobets, Zhezzini Adnan Abbas, 2000)

A possible cause of post-traumatic osteomyelitis can be the corrosion (Pic. 5.3)of dissimilar metals (tires, ligature wire, cramps for osteosynthesis), as a result of the inflammation of soft tissues (in the acidic environment) the corrosion is enhanced, which contributes to the emergence of galvanic currents in the oral cavity (B. G. Apanasenko, 1964; V.A. Malyshev, 1970; A.I. Gritsanov, OF Stanchits, 1974; V.A. Kozlov etc, 1975; B.D. Kabakov, V.A. Malyshev, 198; A.A .Timofeev, E.V. Gorobets, H.E. Scales, 1995, 1996, etc.).

A significant shift of the level of electrochemical potential of the implant in a positive direction points to the development of corrosion release and the occurrence of inflammatory complications in the bone wound (E.V. Gorobets, 2000). It was found that galvanic currents significantly reduce the level of general and local factors of nonspecific defense of the body (A.A. Timofeev, E.V .Gorobets, Zhezzini Adnan Abbas, 2000).



Pic. 5.3. Post-traumatic osteomyelitis of the mandible, which is caused by the cramps corrosion: a) knitting needles, b) corrosion of dissimilar metals (spokes and miniplates), c) and d) - stainless steel wire

A.I. Nerobeev provided the pathogenesis of post-traumatic osteomyelitis of the mandible (1969) as follows; oral bacteria get into the fracture gap through the torn mucosa of the alveolar outgrowth, it commits to the hematoma in the area of primary bone necrosis and soft tissue, blood clot breaks down and the focus becomes infected. Because of the fact that the destruction processes in soft tissue are more pronounced, the greatest activity of the pathological process is observed at the lower edge of the mandible, it means, there where is the main muscle mass. From the odontogenic lesions, microbes penetrate further into the damaged area of bone, helping to extend the zone of necrosis.

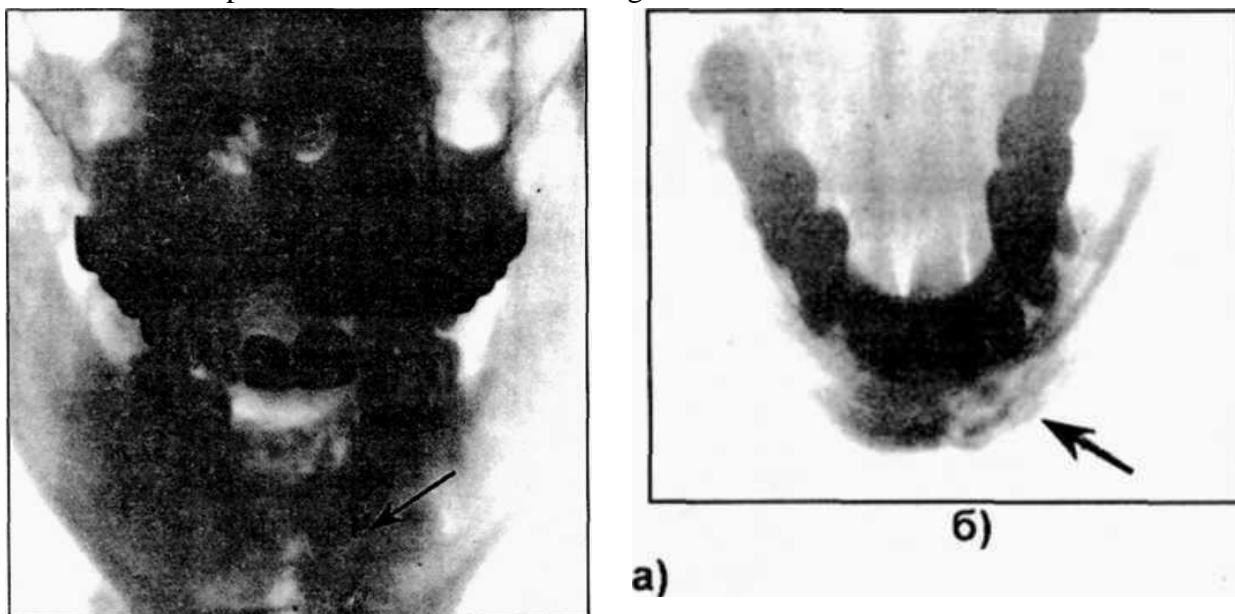
The factors that contribute to the development of post-traumatic osteomyelitis are: the latest treatment of patients for the rendering of specialized medical care, lack of effective reduction and fixation of the damaged fragments of jaws, the presence of concomitant traumatic brain injury, multiple injuries of the jaw or the presence of fragments, pronounced soft tissue injuries in the area of the fracture, the presence of erupted teeth that are in the fracture crack; focuses of chronic odontogenic infection, the damage of the neurovascular bundle, abscess near the jaw of soft tissue; diseases, contributing to the general and local nonspecific host defense, corrosion of metal cramps, violation of the regimen by the patients, etc.

The removal of sequesters in the post-traumatic osteomyelitis of the jaw is necessary, because it was shown that the sequesters only serve as a reservoir of microflora and are practically useless for minerals reception, needed to build the bone spur (A.I. Nerobeev, 1969).

Microorganisms that are found in pathological focus of patients with posttraumatic osteomyelitis of the jaw were more often represented by staphylococci, streptococci, proteus and escherichia coli (can be in

associations), more less were represented by the bacteroids, fusobakterias, peptostreptococci and other anaerobes.

The clinical course of post-traumatic osteomyelitis can be *acute* or *chronic*. It should be noted that in the acute stage of the disease is often difficult to determine whether a patient has a developing of the post-traumatic osteomyelitis or bone wounds abscess, as in both cases, the inflammatory manifestations in the soft tissues predominant, which are located around the fracture crack. The acute stage of osteomyelitis is often overlooked that can be attributed to the free outflow of inflammatory exudate from the crack of the fracture. Radiography of the mandible in this period of the disease has no diagnostic value.



Pic. 5.4 Post-traumatic osteomyelitis of the chin of the mandible: a) survey radiographs; b) spot radiographs of the chin of the mandible

The acute phase of post-traumatic osteomyelitis may develop as in the first days after injury, and after 7-10 days. The general condition of the patient worsens because of the growing symptoms of intoxication. The pains in the field of fracture increase. There is edema and inflammatory infiltration of the soft tissues that surround the fracture crack. In the future, it may be complicated by the development of an abscess or cellulitis. The patient complaints and clinical symptoms depend on the localization of the fracture and on the localization of the formation of a purulent focus in the admaxillary soft tissues, the presence of non-deleted tooth (which prevents the exit of pus) in the fracture crack. From the part of the oral cavity there is also swelling and infiltration of the mucosa and periosteum, it can be formed submucosal or subperiosteal abscesses. There are not radiological signs of osteomyelitis in the acute stage on radiographs of the mandible. No earlier than two weeks after the development of inflammation in the bone, it may be radiographically defined the extension of the fracture crack with signs of osteoporosis, and along the line of the damaged jaw are detected sequesters with different shapes and sizes.

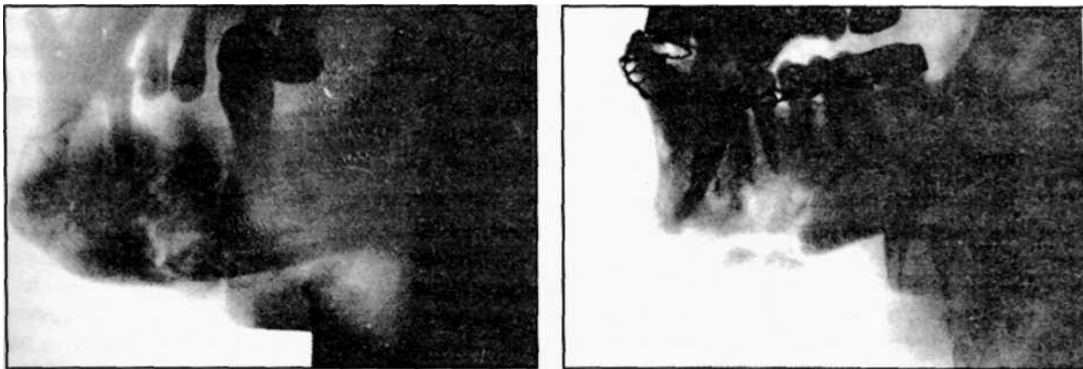
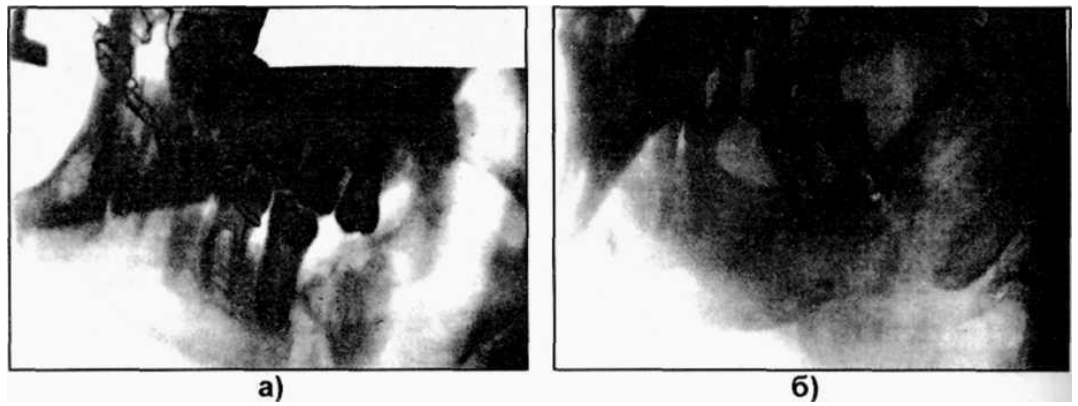


Fig. 5.5. Lateral radiographs of the mandible of patients with post-traumatic osteomyelitis of the angle (a, b) and body (c, d).

Subacute stage of the process is difficult to identify because of the paucity of clinical symptoms of this period.

In the chronic phase of post-traumatic osteomyelitis, the inflammatory infiltration and edema of the admaxillary soft tissues are preserved, it is formed fistula with a scanty purulent discharge. There is not usually luxuriant granulations, that is characteristic for odontogenic osteomyelitis. Fistulas can be either on the skin, either on the mucous membrane, that function for a long time. When there are complications of post-traumatic osteomyelitis with actinomycosis it can be formed multiple, persistent fistulas with the release of crumblike pus. The chronic stage of the disease may be aggravated (Pic.5.4.).

On radiographs of the lower jaw at the edges of bone fragments there is a zone with areas of resorption of bone destruction (Pic.5.5.).

Along the lines of fracture there are determined boundary sequestrs of varying shape and size. Sequestrs are seldom located away from the fracture line. In post-traumatic osteomyelitis of the mandible it is often noticed a sequestered boundary character, and sometimes these are necrotizing small fragments between the bone fragments of the mandible. Between the bone fragments can be seen more dense shade, indicating the formation of bone tissue (callus).

Thus, *the first symptom that should alert a doctor, it is no tendency to narrow the fracture crack and even its increasing, blurred and uneven edges of the bone fragments.* It is very difficult to catch the moment when the piece takes on the characteristics of the sequestrs. According to A.T. Rabuhina (1973), the bone fragments, relatively quickly, within 10-20 days, change the form: they reduce in volume, and their edges become less sharp, there is not an increase in the intensity of the shadows when comparing a series of radiographs. These features help the doctor to clarify the diagnosis. An early sign of incipient consolidation of the fracture fragments will be the appearance of delicate periosteal layers along the base of the mandible. According the surveillance of N.A. Rabuhina (1973), with full clinical well-being, during 8-9 months the gap

between fragments is filled with bone tissue, which has no characteristic functional orientation of its structure, and the restoration of the latter occurs gradually, for over 4-5 months. However, even after 13-16 months the line of the fracture can still be detected. If unremoved small sequester left, their shadow, gradually decreases in size and will be visible after 6-7 months (N.A. Rabuhina, 1973).

The diagnosis of post traumatic osteomyelitis is established on the basis of the collection anamnestic data, of the patient complaints, the presence of clinical and radiological signs of fracture of the jaw at different stages of the consolidation of the bone tissue, inflammatory manifestations in the area of damaged bone.

Post-traumatic osteomyelitis of the jaw is not subject to self-cure.

The treatment of patients in the acute stage of the disease consists of a promptly abscess disclose on conventional methods (see the relevant chapters of this manual), of an adequate drainage of purulent wounds, dental health (the tooth is removed from the fracture gap), ensuring of the immobilization of the moving jaw fragments (in the case this was not done earlier), the appointment of anti-inflammatory and restorative treatment (see the relevant sections of this manual), hygienic oral care.

In the chronic stage of the flow of post-traumatic osteomyelitis, measures are being taken to speed up the regenerative processes in the bone injury, and after the rejection of seizures there is a sequestrectomy operation. The most optimal time to perform the surgery is 3-4 weeks after the fracture. However, in some cases, when the sequester is a splinter of bone, surgery may be performed two weeks after the injury. In slow flowing of reparative processes in the jaw, the terms of surgery can increase up to 5-6 weeks.

Sequestrectomy should be done more extraorally, at least - both inside and extraoral. By removing the sequester it need to take care not to break down fibrous adhesions between the bone fragments. It should be scraped only pale, flabby granulations. It should be remembered that sequesters must delete everything (including the small ones), as well as teeth, the roots of which are not covered by bone tissue. If you find, or there is a message with the mouth it needs to isolate the surgical wound by suturing the mucous membrane. Having discovered during the operation the bone defect, it needs to be filled with hydroxyapatite (alone or with antibiotics), bioceramics or bone graft. If during surgery it is revealed an abnormal mobility of bone fragments, it is necessary to conduct a delayed osteosynthesis of the mandible (with titanium miniplates alone or coated with bioceramics). Keep in mind that at all stages of the treatment of post-traumatic osteomyelitis it needs a strong immobilization of bone fragments.

The outcomes of treatment of the disease is usually favorable, it means that full restoration of anatomical and functional characteristics of the mandible are observed. In some cases, post-traumatic osteomyelitis may be complicated by the formation of a false joint, jaw deformity, improper healing of bone fragments, sepsis, etc.

Prevention of post-traumatic osteomyelitis consists of a timely and a correct delivery of specialized medical care to victims with damaged jaw (including fixation), as well as the removal of the factors contributing to the development of inflammatory complications in patients with fractures of the jaws.

GUNSHOT JAWS OSTEOMYELITIS

The osteomyelitis is the most common complication of gunshot injuries of the facial bones. According to the I.G. Lukomski (1942), this complication of injuries are almost inevitable. D.A. Entin and V.M. Uvarov (1951) noted that osteomyelitis complicates the course the gunshot fracture of the mandible with 43,4% and the upper jaw - with 25,8%.

Differences between the gunshot and post-traumatic osteomyelitis due to the following:

- the mechanism of bone lesions;
- the presence in the gunshot wound of free lying bone fragments (of which the primary sequesters may be formed) and damaged areas of bone that did not loose contact with the periosteum (of which can be formed

secondary sequesters);

- the presence of areas of bone that have undergone molecular concussion (as a result of a gun shooting - a bullet or a bullet fragment). In these areas of the bone tissue the metabolism is disturbed, although apparently they do not differ from intact bone (in the future of them can be formed tertiary sequesters);
- the presence in the gunshot wound of foreign bodies (bullets, fragments of shells, teeth, etc.);
- there is an infection when there is an open gunshot osteomyelitis;
- the gunshot bone wound almost always has a wide communication with the cavities (mouth, nose, maxillary sinus) and is subjected to further infection.

Thus, the gunshot osteomyelitis is a purulent-necrotic process in the damaged areas of the jawbone, which did not loose connection with the surrounding tissues (periosteum or soft tissue), as well as in apparently unaltered areas of bone, affected by molecular concussion.

The most appropriate ordering of gunshot osteomyelitis of jaws is the classification of V.I. Lukyanenko (1986).

Table 5.1.

The classification of gunshot osteomyelitis of the jaws (by V. I. Lukyanenko, 1986)

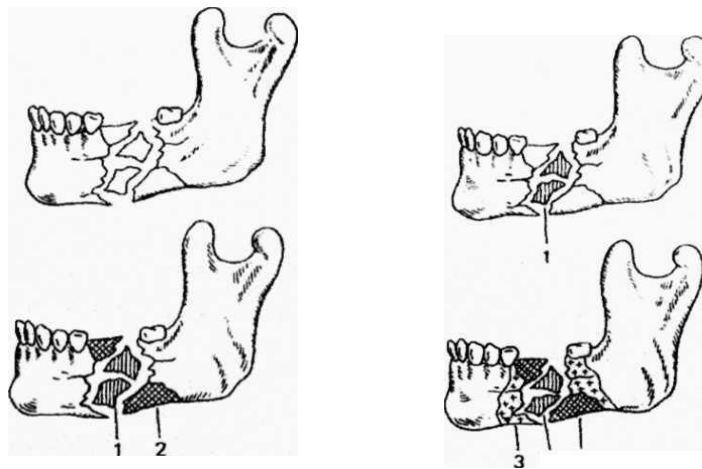
By the clinical course:	<ul style="list-style-type: none"> - acute - subacute - chronic - exacerbation of chronic
By morphological nature of the process:	<ul style="list-style-type: none"> - destructive and plastic - destructive - destructive-necrotic
By the localization of the process:	<ul style="list-style-type: none"> - of the upper jaw - of the lower jaw - of both jaws
By the nature of complications:	<ul style="list-style-type: none"> - without complications - with complications (abscess, cellulitis, etc.)
By the condition of consolidation of the jaw fracture:	<ul style="list-style-type: none"> - no signs of consolidation - with initial signs of consolidation - in the presence of adhesions fragments

The clinical course of gunshot jaws osteomyelitis is diverse and depends on the patient's age, location and stage of the process, of morphological changes in bone and other causes. The course of gunshot osteomyelitis of the maxilla occurs more benign than the lower (due to the anatomical features of the structure of the jaw). The favorable course of osteomyelitis, with a gunshot wound, is associated, with one hand, with the fact that this osteomyelitis occurs in unsensitized body, and with another hand – that this occurs to young people, it means, at a high reactivity of the body. General and local clinical symptoms of gunshot osteomyelitis is similar to its other forms (odontogenic, post-traumatic), it means, for all types it may be deteriorated the general condition of the body (it depends on the severity of the current process), it is accompanied by abscesses and phlegmon of admaxillary tissue, fistula may be formed, sequesters are formed, etc.

The clinical features of gunshot osteomyelitis are as follows:

- primary, secondary and tertiary sequestrers are formed (Tab. 5.1.,Pic.5.6.);
- foreign bodies may be in the gunshot wound (bullets, fragments, etc.);
- damaged tissues are around the bone wound (scar tissue), that are on some stage of reparative regeneration and fistulas are located in the oral cavity, and on the skin;
- there are additional focus of bone wound infection of the adjacent cavities (mouth, nose, maxillary sinuses);
- it is accompanied by a disfigurement face, differently expressed (as a result of soft tissue injuries);
- it takes place in an environment that significantly impairs the reception by the victims of food and liquids;
- the sensory nerve damage causes a loss of pain, tactile and thermal sensitivity;
- it develops in the presence of poor oral hygiene maintenance, as cleaning the mouth is difficult because of the injured surfaces, of cicatricial changes in the tissues, the reduced salivation (with injuries of large salivary glands), worsening of motion of the lips and cheeks (in case of the facial nerve damage).

The gunshot jaws osteomyelitis treatment depends on the stage of the process and consists in carrying out surgery (opening of an abscess or sequestrectomy, depending on the limits of its implementation, a thorough removal of altered tissue, etc.), antibiotic therapy, detoxification, and restorative therapy, physical therapy and immuno-therapy. I find the statement of V.I. Lukyanenko (1986) being correct, that the most "optimal time for surgery for gunshot osteomyelitis is a period during the wound healing process in which a gunshot wound, on the one hand, there is the awakening of the maximum regenerative capacity of tissues, and on the other there is more or less clear demarcation of seizures." This period typically corresponds to 6-8 weeks after injury, it means, these terms are most suitable for sequestrectomy.



Pic.5.6. Schematic representation of the origin of sequestra (by V.I. Lukyanenko): 1 – primary, 2 – secondary, 3 - tertiary sequestra.

The prevention of the gunshot jaws osteomyelitis consists of a timely, correct and complete rendering of pre-hospital (first aid, pre-hospital and first medical) and hospital (skilled and specialized) medical care to the injured person in the maxillo-facial area.

VIOLETION OF REPARATIVE REGENERATION OF THE LOWER JAW

The violation of reparative regeneration of the mandible bone tissue can be manifested in the form of:

- delayed consolidation of bone fragments;
- jaw bone defect;
- ununited fracture;
- false joint

The reparative regeneration of the mandible is described in detail in section 18.4. However, the normal period of consolidation of bone fragments may be delayed for 2-4 weeks and there is a *delayed consolidation*. This is facilitated by general and local causes. Among the common causes a significant role has the pathological osteoporosis (compared to age-related changes, metabolic disorders, digestive disorders, disturbances of water and salt and protein metabolism, blood diseases, etc.), it occurs in vitamin deficiency, infectious and endocrine disorders, rheumatoid arthritis, systemic lupus erythematosus, burn disease, etc. The local causes are: poor fixation of bone fragments and their displacement, soft tissue interposition, neuro - trophic disorders associated with damage of the mandibular nerve - vascular bundle; inflammatory complications in bone, the emergence of galvanic currents, etc. A clinical evidence of delayed jaw consolidation is a gradual increase in strength at the junction of the fragments (in fracture), the observation of patients in the dynamics of its treatment (after a certain period of immobilization). A single X-ray has not diagnostic value, as it can not distinguish ununited fracture of the lower jaw as a result of delayed consolidation.

The treatment consists in removing the causes of delayed consolidation and the appointment of the funds to accelerate the regeneration and the improvement of reparative defenses of the patient.

According to the A.A. Skagera (1981), the criterion in the diagnosis of "bone defect" is the presence or absence of disturbances of form and function of the jaw after joining the ends of the fragments in the light of compensatory processes of bone as an organ. The authors note that a change in the bite occurs in shortening of the lower jaw more than 2-3 mm, and with toothless jaws prosthesis can be compensated by a shortening of the mandible up to 5-7 mm. In the presence of a defect in the jaw greater than 1 cm in an attempt to compare and fix the ends of the fragments, violations of the temporomandibular joint arise.

In the case of ununited fractures of the mandible the crack is filled by a coarse-fibered connective tissue, which prevents the regeneration of bone. In this tissue can be detected only small areas of cartilage and bone tissue. Clinically, you can find a small mobility of the fragments, making it difficult to complete the process of chewing. The treatment consists in removing not only the coarse-fibered connective tissue, but also in all refreshment of the sclerosed fragments, followed by the creation of optimal conditions for reparative bone regeneration (reduction and fixation of bone fragments, etc.).

Pseudarthrosis is a persistent violation of the ossification of the bones, characterized by rounding and smoothing of the ends of the fragments with a filling in the fracture crack by a coarse-fibered connective tissue and the presence of abnormal motility. Clinically, it manifests a significant amount of movement of the jaw in an unusual place. On radiographs of the edges of each fragment can clearly be seen the closing compact disc. The causes of a false joint, or ununited fractures consist in the violation of the relative regeneration of the mandible. Its reasons are similar to previously stated. The treatment is surgical with the urgent removal of the closing compact disc by the edges of the fracture crack, followed by fixation (in the absence of the jaw defect) or bone grafting (with a defect larger than 2 cm).

COMPRESSION SYNDROME

In the conduct of hostilities, or in extreme situations, wounded in the maxillofacial region may be under the rubble of collapsed buildings, etc. It develops traumatic toxicosis to the injured. The dentist should be aware of this complication.

Compression syndrome (synonym: crush syndrome, traumatic compression syndrome) is a pathological condition that develops as a result of prolonged (4-8 hours or more) crushing of the soft tissues of the extremities by the rubble of destroyed buildings, blocks of the pound with collapses, bombings, earthquakes, etc.

During a prolonged crushing of tissues of the lower and (or) of the upper extremities, as during any mechanical trauma, the body is affected by three factors:

- the pain (a complex of neurohumoral and neuroendocrine disorders, characteristic to a severe stress).

Topic № 6

THERMAL DEFEATS

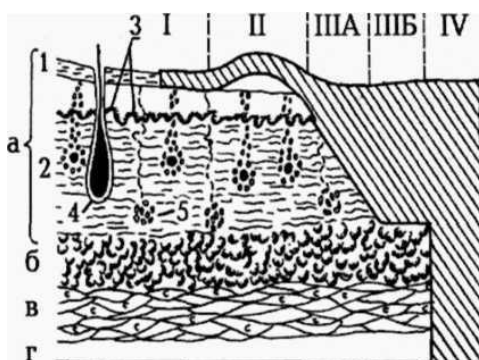
1. BURNS OF SKIN FACE AND MUCOUS MEMBRANES OF THE MOUTH

2. FREEZING INJURIES

BURNS OF SKIN FACE AND MUCOUS MEMBRANES OF THE MOUTH

Burns - damage of tissue of an organism that appeared in result of local action of high temperature and also a chemical electric current or ionizing radiations.

On etiologic to a sign distinguish following burns: thermal, chemical, electric, radial (radioactive radiation). On circumstances in which there was a defeat: Household, industrial and a wartime. Burns of a face skin can be: Isolated or concomitant with burns of other areas of a body.



Pic. 6.1. The schematic image of depth of defeat of fabrics at burns different degrees

a-skin (1 - false skin, 2- derma, 3- sprout a layer of false skin, 4- Hair bulb,5-sweat gland); б – hypodermic cellulose; в – muscle; г-bone.

- 1 degree- The top layer of false skin is amazed;
- 2-degree-exfoliate the top layer of false skin with bubble formation;
- 3 a-degree- cambial elements of derma are kept
- 3 б-degree- skin in all thickness is amazed;
- 4-degree- the skin and the tissue is amazed.

In our country four-sedate classification of burns by depth of defeat of tissue is accepted:

1 degree- Is available hyperemia and moderately expressed puffiness of the skin, moderated sickliness. These changes are liquidated for 3 5 days. Blankets of epidermis are listening and burn surface is epithelial zed independently. On a burn place remains to different degree of expressiveness pigmentation which in later completely disappears.

2 degree- Peeling of a horn layer of epidermis misty liquid is characteristic (On structure close to plasma blood). Are formed into epidermis the bubbles which bottom is basal a layer of epidermis. Fibers papillary layer are loosened, nipples are smoothed. In thickness of the derma blood vessels are expanded, capillary stasis, hemorrhages. In a day after a burn in a bubble liquid there are leukocytes. Comes leukocyte infiltration of derma which is most expressed in nipples an ohm a layer and around epithelial skin appendages. The sharp inflammatory phenomena and hypostasis start to decrease about 3 4 days, and in 7 days the burned surface becomes covered epithelium which has in the beginning no horn layer. Hems doesn't goes from the remained layers of the derma.

3A-degree-here comes destruction of all layers of epidermis, including it sprout a layer, and also necrosis a blanket of derma. The remained deep layers of derma edematous. The hypostasis extends on subject cellulose. The burn surface can be presented by deep bubbles, a scab or that and another. On border of become lifeless and viable cages the demarcation shaft, an in 2 weeks-granulations in a day starts to be formed. Scab tearing away begins. From remained epithelial skin appendages there is a growth epithelium on granulation. At the expense of it burns of 3 degrees heal. The epithelization of the burn surface occurs within 4 6 weeks to formation of hems.

Burns of a face skin and oral cavity mucous membrane

11-b degree-Destruction comes of skin in all its depth. As a result necrosis the scab is formed. In 5 6 days under it begin proliferative processes, formation granulation and its tearing away which comes to an end through 4 5 weeks. After tearing away of the lost tissues is formed the granulating surface which healing occurs iatrical contraction and regional epithelization. Healing terms depend on localization and the sizes of a burn. Clinical it is very difficult to differentiate among themselves burns of 3 and 4 degrees.

4 degree is observed the destruction of epidermis hypodermic cellulose and subject fabrics (bone, muscles,fascia).

Not isolated degrees of defeat of a skin and combinative can be observed on 11-11 degree, 11-111 degree.

Burns 1,2 3-A degree Burns 1 2 3 degree concern to superficial and 4 degree- the deep.

At superficial burns cages of epidermis or epithelial appendages of a skin partially remain as is a source for independent epithelialization a horn surface. At deep burns the integument independently isn't restored.

At superficial burn defeats which occupy to 10 -12% surfaces of the body or deep on the area 5- 6% to the surface of the body to adults, burns proceed as local defeat. At children and old men according to 7 -8% and 3-4 % surfaces of a body. At more widespread burns on the area there are infringements of activity of various bodies (liver, kidney) and systems (Warmly – vascular, respiratory, Gastro enteric path, hematoplasty and others.)

Besides degree of depth of a burn the big role in development of burn illness belongs to size of the area of defeat. More often the burn area it is roughly possible measure a palm of the victim thus in view of that the palm of the adult person is approximately equal to 1% surface of its body. A. Wallace (1951) based on that the area of separate parts of the body of the adult person it is equal 9 % to the general surface of the body, has offered a so-called “rule of the nine”. According to this rule of the surface of the head and the neck makes -9% top extremities -9% bottom extremities -18% back surfaces of the trunk -18 % forward surfaces of the trunk of -18% perineum’s- 1 % from upholster surfaces of a body of the adult person.

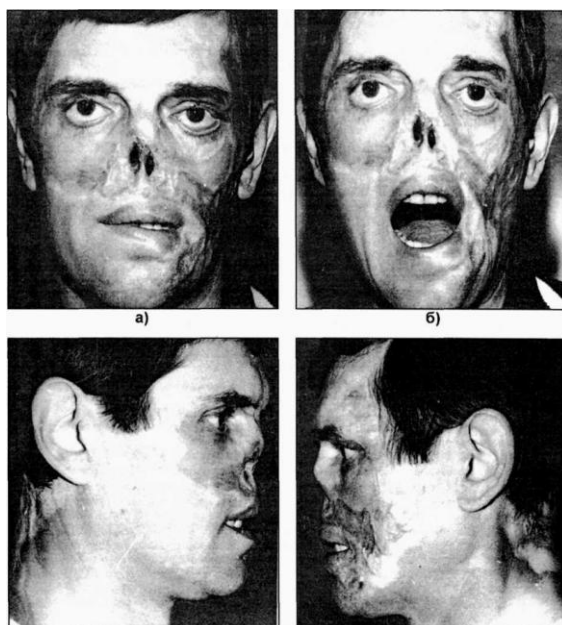
Set of infringements in various systems and bodies which arise at extensive and deep burns it is accepted to name burn illness. During burn illness are distinguish four periods - burn toxemia burn shock burn the septic tank of convalescence. Duration of each period of illness has no clear boundary.

The little shock is observed at superficial burns on the area no more than 20% (deep no more than 10%).Heavy shock at burns on the area from 20 to 55 %. The heaviest shock at burns on the area of 60 % and from above to the surface of the body of the victim (deep - over 40 %).Burn shock proceeds from 2 till 48 hours seldom till 72 hours . During this period there comes display of the second stage of burn illness burn toxemia which to last on the average 10-15 days and gradually passes in (it is characterized purulent-resorptive fever). During burn illness can be observed mental frustration (psychoses, hysterical conditions, depressions and other).

Thermal burns

Action in result of flame, hot liquids (boiled water), pair, the heated metals, burning gases or liquids result and other.

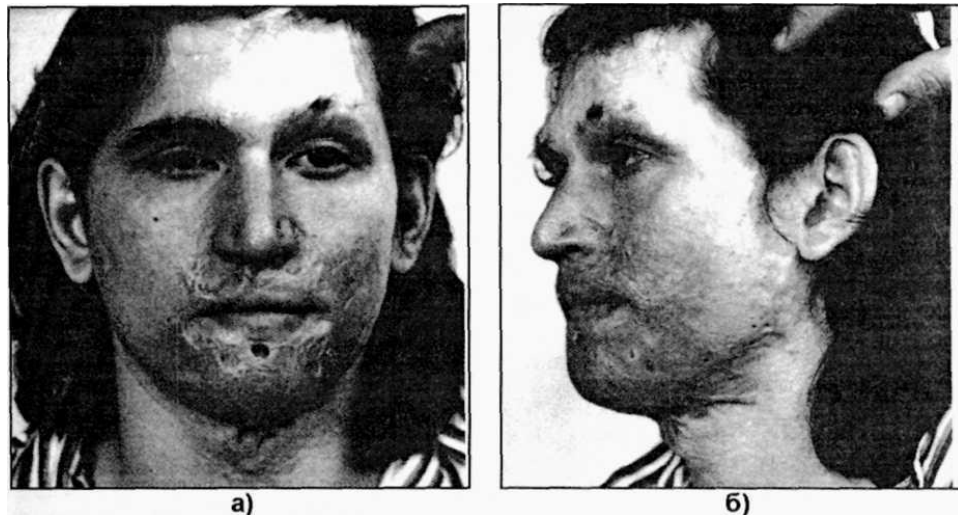
Clinical various degrees of the burn have the semi logy. The burn of 1 degree is characterized by reddening and small puffiness which appears in some seconds after influence of the thermal factor (Boiled water, flame, pair) or in some hours at beam influence. After some hours of a pain start to decrease and disappear in 3-5 days. Damaged epithelium listens attentively on a place of a burn within a month there can be a small pigmentation which independently disappears further. The burn of 2 degrees -differs more expressed semi logy of display hyperemia, a pain hypostasis. Bubbles which are filled in the beginning by a transparent liquid which grows turbid further (because of protein curling) are formed. The sharp inflammatory phenomena decrease about 3 -4 days and in 7-10 days heal without hems. The redness and pigmentation will remain about two months.



Pic.6.2. Iatrical deformation of the person of the patient which had burn boiled water at children's age (a, b -the front view v, g side view).

The burn of 3 degrees is characterized by scab formation. At dry necrosis the amazed skin dense dry brown or black color. Along the edges of a wound scraps scorched epidermis hang down. The skin is tolerant to the touch. At damp necrosis the skin it is gray yellow color it is covered by bubbles. Soft tissue round damp necrosis the edematous. At a burn of 3 degrees it is observed regional or insulin of epithelialization at the expense of remained epithelial appendages and the rests Malpighi an a layer of epidermis. At a burn of 3 degrees after scab tearing away there is a wound which heals by scarring and of epithelialization.

The burn of 3 degree the amazed surface is presented by deeper scab, than at burn degree. The carbonization of tissues is quite often observed. Healing of burns of 4 degrees occurs very slowly, is accompanied by partial or full loss of certain anatomic formations.

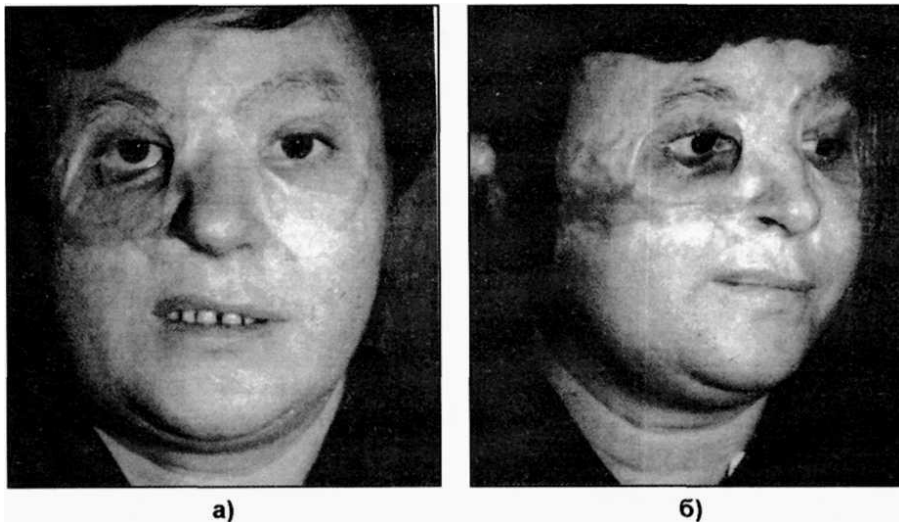


Pic.6.3. Cicatricial deformation of the person at the patient after burn flame (a -the front view, b- side view).

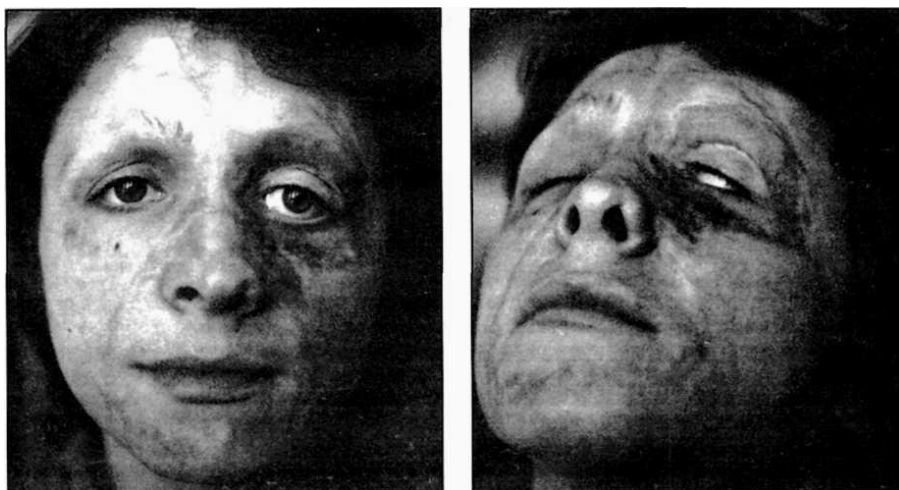The establishment of degree of a burn is based on characteristic clinical symptoms. It is necessary establish the area of burn defeat. Taking into account depth and the area defeat serves as an indicator of weight of a burn an index Frankfranka is deduced from this that is equal to the superficial area 1 ED, and 1% burn deep-3 ED. At defeat, respiratory ways increases 30-45 ED. To easy defeats to 30 ED, average weight from 31 to 60 ED, to heavy from 61 to 90 ED, and the index concerns the heaviest-from above 90 ED.

Particular qualities of burns oral- facial area. The surface of the face makes about 3 % of a total area of the body. Particular qualities oral - obverse area concern: the plentiful innervations, good vascularization, roughness of a relief of the face and the distinguished thickness of the skin on different sites, presence of organs of vision, the beginning of respiratory and digestive paths, a disfiguration of the face leads to mental and functional frustration.(watering ,salivation and other).

Burns of the face cause the expressed hypostasis of soft tissue appearing from the first hours after a trauma and quickly accruing. Because of plentiful innervations arise very severe pains. As a result of roughness of the relief of the face and an unequal thickness of a skin on the separated sites of the face burns formed different degree. Deep burns happen more often on acting parts of maxillofacial. (nose,ears,lips, superciliary arches,chin). There is an expressed hypostasis of eyelids, a hypostasis of a conjunctiva of an eyeball and are possible eyeball burns. The red border of lips is turned out. At burns at oral area, as a result of a hypostasis of lips, the last get a characteristic kind-“of fisher mouth”. At short action of the thermal agent are surprised only open parts of the face. The headdress, helmet, points, clothes collar can protect from a burn the hairy part of the head, blepharons, forehead, neck, ears. The burn of the face is often combined with defeat of the top respiratory (there is a complicated breath and even an asphyxia) ways and a mucous membrane of an oral cavity, a nasopharyngeal, and sometimes and throats.(the hypostasis of the throat and larynges is observed) Food intake, nasal breath is broken, and at over collar of eyelids appears watering conjunctivas and even keratinize.

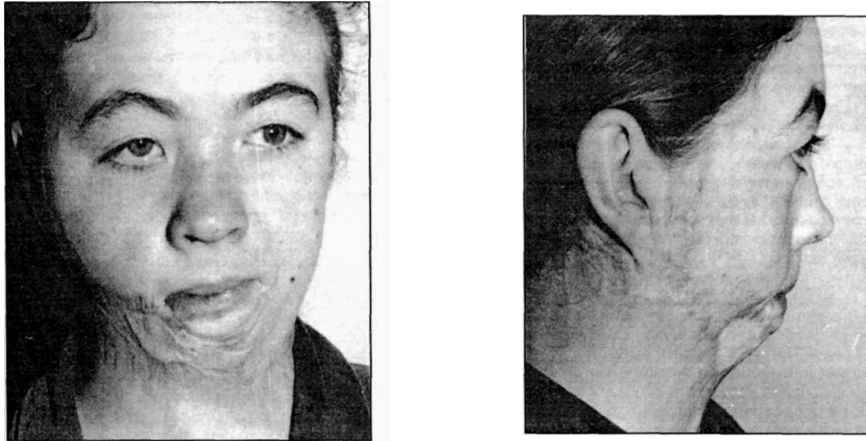


Pic.6.4. Cicatricial deformation of the average face zone at sick with presence you gate of a lower eyelid and epicanthus. (a-the front view, b-side view).Burn burning gas.

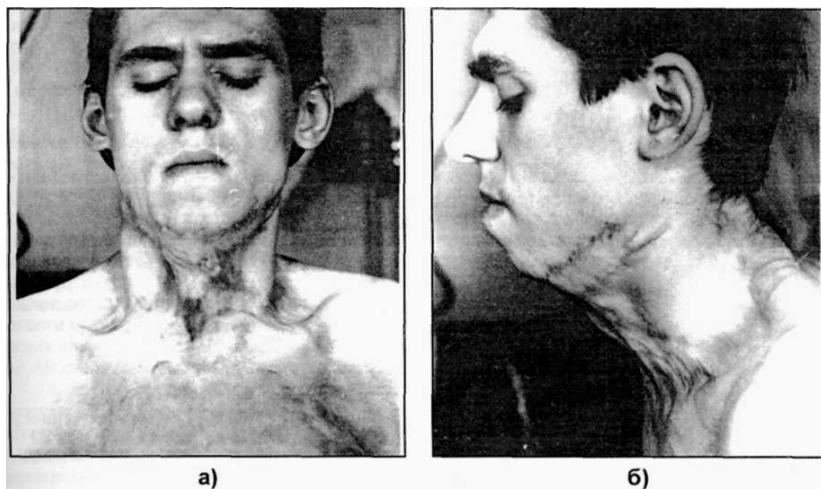


Pic.6.5. Cicatricial deformation of the face (a-the front view, b-side view).Steam burns

As a result of burns of soft tissue oral - obverse area there are after burn scar face skin and neck deformations, you collars bottom and upper eyelids or lips, microtome, defects and deformations of auricles or nose wings and other. (Pic 6.2.-6.7.).



Pic.6.6. Cicatricial deformation of the bottom part of the face and neck (a-the front view; b side view).Scalds.



Pic.6.7.Cicatricial deformation of the neck and of the top third of thorax (a-.the front view, b-side view).Scalds.

Treatment. First aid at burns appears on the scene. It consists of the actions directed on cancellation of the thermal agent. That will reduce duration of tissue hyperthermia and to reduce depth of damage of tissue it is necessary quickly cool the damaged site accessible means. Immersing in cold water impose with the towel moistened in cold water, put a bubble with ice and other). If there is no possibility to apply the cold, the narrowing surface is necessary to leave open for cooling air. The patient is placed. The provision of the first medical aid it is impossible to spend any manipulations on burn wounds.

Before transportation of the victim the burned surface close an aseptic bandage .On the face of the bandage it is possible not to impose. Pre-medical rendering assistance owes the life is directed on preventive treatment of burn shock, to the patient enter analgesics, antihistamines and cardiovascular preparations. It is impossible to apply on the burn wound of ointment on the fatty basis, and also painting and tanning means complicate further a toilet of the wound and will complicate definition of depth of a burn.

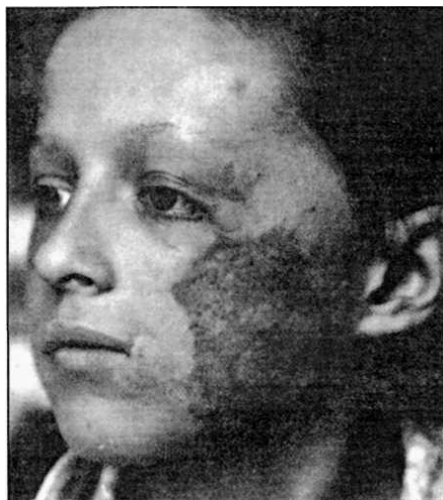All victims were directed to the hospital. Out-patient treatment is possible only at burns of 1 or 2 degrees on the limited site of the body. All other victims must be hospitalized. In the hospital was spent antishock therapy which includes appointment of following medicines analgesics, antihistamines preparations, analeptics (cordiaminum, corazolum, bemegridum,) corticosteroids ;(prednisolonum,

hydrocortisone) ; inhibitors proteolysis (contrycal); cardiacs, substances stimulating metabolic processes; vitamins urinate and under indications, symptomatic treatment.

Local treatment of the burned patients were spend in pure operational after preliminary introduction to the patient of anesthetics. (2% solution promedol). Skin round the wound treated with the napkins moistened with 0.5% solution of ammonia or warm soap water. Then it drained with spirit or, iodine. The gauze balls moistened with solutions of antiseptic tanks with anesthetics remove from the burned surface scraps of epidermis and foreign bodies. Small bubbles don't open. Big bubbles cut pressure and empty. High voltage bubbles strike and emptied. Exfoliating epidermis, sticking to wound surfaces, carries out the role of a biological bandage and such way accelerates epitilization wounds. At burns of 1-2 degrees on the amazed surface was put a preparation tsiminal trimekain, dimethyl sulfoxide and other components. Burns of the face treat opened by a method less often (at deep burns) –closed.

For treatment of burn wounds is used 20% gel of granules quercetin immosgent polymethylsiloxane lysozyme ointment preparations which is polyethylene glycol .At an infection of wounds treatment is carried out according to all rules of purulent surgery. Plastic operations are spent only on pure granulating wounds which prepared in the course of conservative treatment. On the face for free change use only continuous skin rags and perforations on the rag it is impossible to do it, worsens cosmetic effect.

In process of healing of burn damages of a skin with a view of the prevention of scar deformations massage is spent. In the stage of swelling of the hem it is possible to apply to preventive maintenance of hypertrophic hems electrophoresis with lidazy iodine. Phonophoresis with the hydrocortisone or propolis paraffin microwave therapy and other. Through 1.5 mouths after healing of the wound for acceleration of maturing of hems and the prevention retraction tissue appoint balneotherapy, fangothrapy and other.



Pic.6.8. Cicatricial deformation of the face of the child after contact of burn about the heated metal.

Features of thermal burns at children. The most frequent reason of burns is hit on a skin of hot liquids, a touch to the heated metal subjects or the burn flame (Pic.6.8).

The burn area should be determined taking into account the child's age. You can use this table Uolesa. (A.wallace,1951)

Burn disease in a child may develop in lesions of only 5% of body surface.

Burn disease in the child may develop in lesions of only 5% of body surface. Especially in younger age groups; The younger child that proceeds burn illness more hard. Deep burns on the area of 10% of the body surface are considered as the critical. Children under the age of three years the shock was developing if the burn area of 3-5% of body surface and in the older-5 to 10%. Burn shock at children proceeds more hard than at adults (faster there are changes in albuminous and water and electrolyte an exchange hypovolemia haemodynamics infringements uropenia and other).

Except earlier specified reasons of burn at children thermal damages of the mucous membrane arise at reception of hot food (soup, milk). First of all is damaged the mucous membrane of lips of forward department of language and hard palate. There is congestion the hypostasis and shamorbidity of the mucous membrane. Can be formed inside epithelial bubbles which very quickly burst and there are scraps of epithelium against hyperemic bases.

Among early local complications can arise keloid hems of the contracture neck stomatitis lymphadenitis and other among general- pneumonia an otitis nephrite and other. Infringements from mentality at children happen more expressed than at adults.

Local treatment is carried out by the same principles as at adults. At defeat of the mucous membrane of the mouth appoint applications of 0,5 % by a solution novocain, 0,05 % solution lysozyme ,calendula tincture(1 tea spoon set in a water glass) and other.

After burns children proceeds structural, functional and system rehabilitation long time. Children with burn consequences are subject to prophylactic medical examination before the termination of growth of the organism.

Chemical burns

More often are caused by inorganic acids (sulfuric hydrochloric nitric) alkalis (not slaked lime caustic potassium or sodium and other), salts of some heavy metals (silver nitrate and other). Open sites of the body are surprised basically. At casual reception of acids or at suicide attempts are possible burns of the mucous membrane of an oral cavity, or pharynx and a gullet . Depth of defeat of tissue depends on concentration of chemical substances of their temperature and duration of contact to the skin or mucous membrane. The mechanism of action of acids and alkalis is distinguished.

Acids change the condition of biological liquids (colloid) of cages, occurs dehyitration and coagulation of tissue develops dry (coagulator) necrosis. Salts of heavy metals on the action mechanism stand more close to acids. **Alkalis** cooperate with squirrels and formed alkaline albumin, saponified fats that promotes development damp of necrosis.

Chemical burns, and thermal, share on four degrees (on depth of defeat tissue). But at chemical burns of 2 degrees bubbles aren't formed. Burn illness develops seldom, but in the wound, as a result of chemical interactions, are generated aggressive substances, which absorbed in blood and cause intoxication.

Chemical burns have following features: Are limited on the area with a clear boundary and formations of trace spreading chemical substance. On the skin as it is already earlier told chemical burns proceed in the form of dry or damp necrosis. Mucous membrane at chemical burn it becomes sharp hyperemic. Further appear necrotic sites impregnated exudate and covered with a dense film of fibrin. Under this film there is a wound healing its tearing slow away.

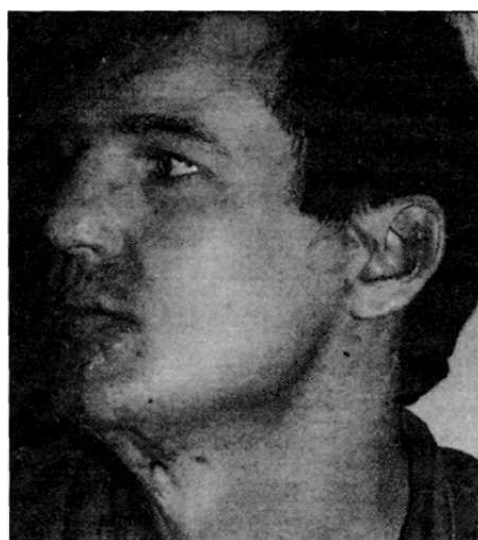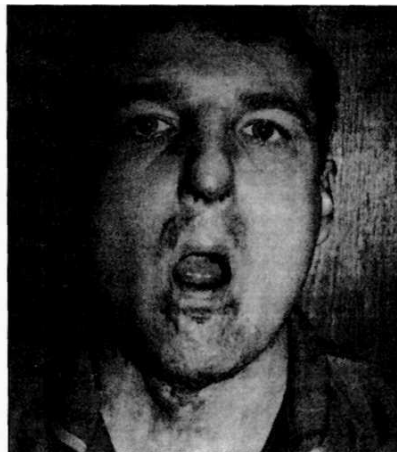
Weight of chemical burn considerably depends on timeliness and qualified the rendered medical aid. It is necessary to neutralize as soon as possible the aggressive factor not only from a skin and mucous membrane surface but also from outside gastro- intestinal path. Wash the amazed sites through the aid of flowing water. At timely rendering assistance washing of the amazed site lasts 10-15 minutes and delayed 40-60 minutes. It is impossible to wash water burns caused by the concentrated sulfuric acid and quicklime (incorporating to water these substances give exothermic reaction that additional has thermal an effect) and also burns of organic connections of aluminum (at interaction with water these substances ignite and delete their alcohol, gasoline ,kerosene).

a)



a)

b)



c)

Pic.6.9.Cicatricial deformation of the face of the patient after chemical burn. Microstoma (a,b) front view at the patient; (c)-side view at the patient

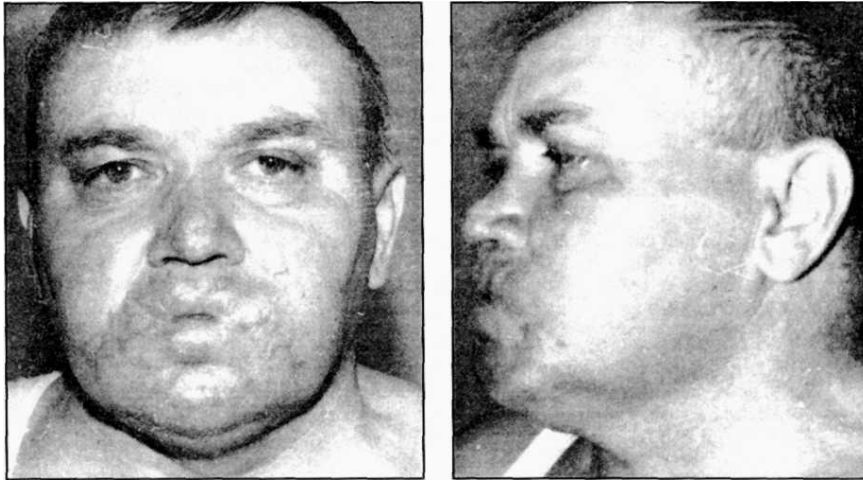Further it is necessary to spend chemical neutralization of aggressive substances: Acids-2-3 % a solution of hydrocarbonate of sodium; alkali-1-2% a solution of acetic or lemon acid; 0,5-3% solution of boric acid; quicklime-20% a solution of sugar; carbolic acid-glycerin;

Chromic acid-5 % solution thiosulfate natrium (Sodium hyposulphitum); Salts of heavy metals-4,5% a solution of hydrocarbonate sodium; burn phosphorus-5% solution of permanganate potassium; Phenol of 40-70 % ethyl alcohol;

At burn of a gullet for removal of pains and a spasm appoint warmly - damp inhalations with anesthetics. Presence of signs of the general intoxication require out detoxification and therapy antidote demand. At burns of the throat and gullet of the patient should be hospitalized.

Local treatment of burn wounds for chemical agents doesn't differ from that at thermal burn, is spent by the general rules.

As a result of chemical burn there are expressed deforming hems (Pic.6.9-6.11).

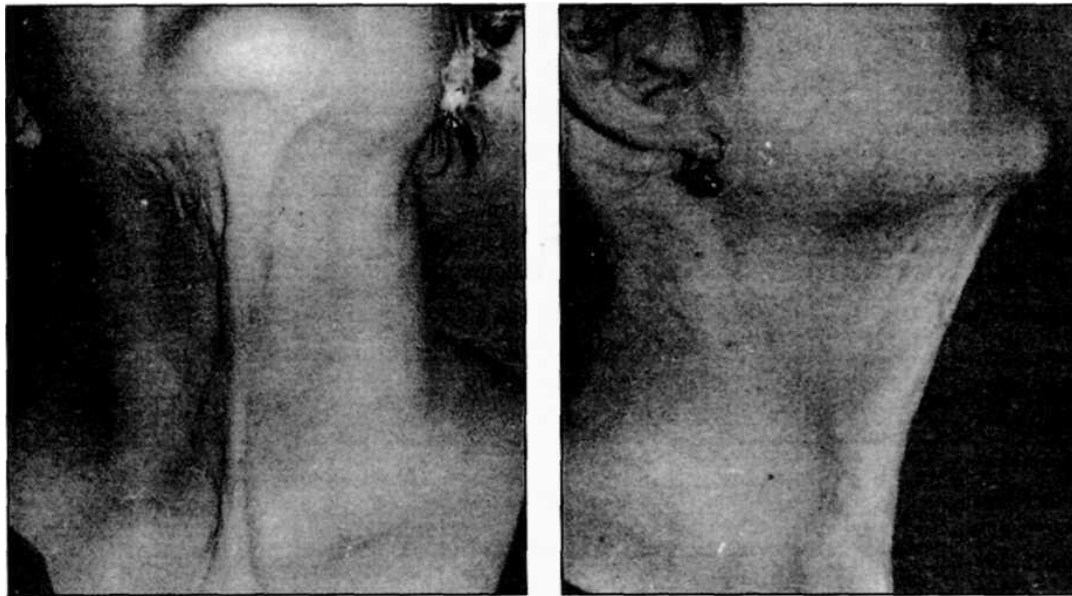


a)

b)

Pic.6.10.Cicatricial deformation of the face of the patient after chemical burn. Microstama.

a) There is a defect of a wing of a nose



a)

b)

Pic.6.11.Cicatricial deformation of the neck of the patient after chemical burn.

a) front view

b) side view

Electric burns

Meet in oral- obverse area seldom. Arise from the electric current action which contact to tissue leads to transition of electric energy in thermal which occurs coagulation of tissue and necrosis. Along with local changes is observed change of function of cardiovascular system and breath. .Can occur respiratory standstill heart fibrillation convulsive reduction of muscles consciousness loss. In place of contact of an electricity with the skin are available a sign on a current-change of the skin in the form of painless eminences of epidermis. In place of defeat by lightning appear lightning sign-change of skin in kind a tree it

is visible the branched out strips of dark red color. Feature of electro burns is that skin defeat usually local and subject tissue.(celluloses fascia muscles)-deep.

Local treatment of electro burns and deep thermal burns practically doesn't differ among themselves, is spent by the same principles.

Beam burns

Beam burns result from local influence on an ionizing radiation skin.

Soft x-ray radiation and particles get into tissue on small depth and cause defeat only to skin. Rigid X-rays and also at radiation possess more getting ability and cause damage not only skin but also subject tissue.

Beam burns can be a consequence of local irradiation of tissue at beam therapy hit on the skin of radioactive substances.

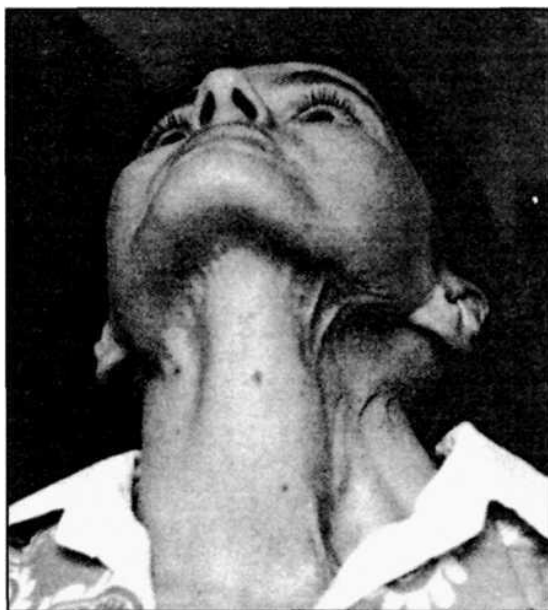
Distinguish four periods of development of beam burns:

First period- **early beam reaction** - is characterized by occurrence erythematic in some hours or days after defeat;

The second period-**latent period**- erythema disappears also clinical implication isn't present (Lasts from several hours about several days and even weeks);

The third period-acute inflammation-appears secondary erythema erosion and ulcer bubbles.

The fourth period -**restoration**- healing of erosion and ulcers on which place are marked tropic frustration.



Pic.6.12. Atrophic hems on the neck at patient after beam therapy

Distinguish three severity levels of beam burns. Burns of easy degree-early of reaction aren't present, the latent period more than 2 weeks, in the third period appears erythema. (against to background, burning itch). In 1-2 weeks clinical displays abate and on the amazed sites is marked the hair, peeling and pigmentation of skin and brown color.

Burns of average degree - an early stage in kind of erythema. In an acute inflammation appears expressed erythema, on its place are formed bubbles, increasing in sizes, further blend among themselves. At opening of bubbles it is formed bright red erosive peptic-ulcer of erosion ulcer-atrophic. The restoration

period proceeds 4-6 weeks and more. Skin in defeat sites thins and pigmented there can be sites hyperkeratosis and telangiectasia.

Burns of heavy degree-in early stage appears painful erythema against of hypostasis of tissue. The latent period lasts less than week. In the acute inflammation period the hypostasis, the lowered sensitivity of the amazed sites dot ulcers very slow develops hyperemia. Ulcers can recidivate. The regenerative period lasts within several months

On place healed ulcers are formed atrophic or hypertrophic hems on which there are the ulcers inclined to neoplastic.

Treatment of beam burns a little than differs from local therapy of thermal damages. It is necessary to remember that healing of beam burns is slow. Therefore in a complex of local medical actions it is necessary to appoint ointments which promote tearing away of necrotic weights and accelerate wound healing. At intoxication therapy is spent disintoxication. There is recommended nutrition.

Freezing injury

Freezing injury-the damage of tissue caused by local influence of cold.

On features of occurrence the freezing injury is distinguished by their following kinds:

1. At ambient temperature more low 0C. (the more low ambient temperature and above humidity, the arises defeat faster).

2. At ambient temperature above 0C (result long cooling at high humidity):

3. Contact frostbite-arises at direct contact of skin or mucous membrane with the cooled metal subject.

On development of pathological process in time distinguish two periods a freezing injury:

To reactive- the period of cooling of tissue (morphological changes in tissue are minimal);

Reactive-comes after warming tissue. During this period all pathological changes are shown completely.

On depth of defeat distinguish 4 degrees of freezing injury:

1 degree-the blanket of epidhermis is amazed only;

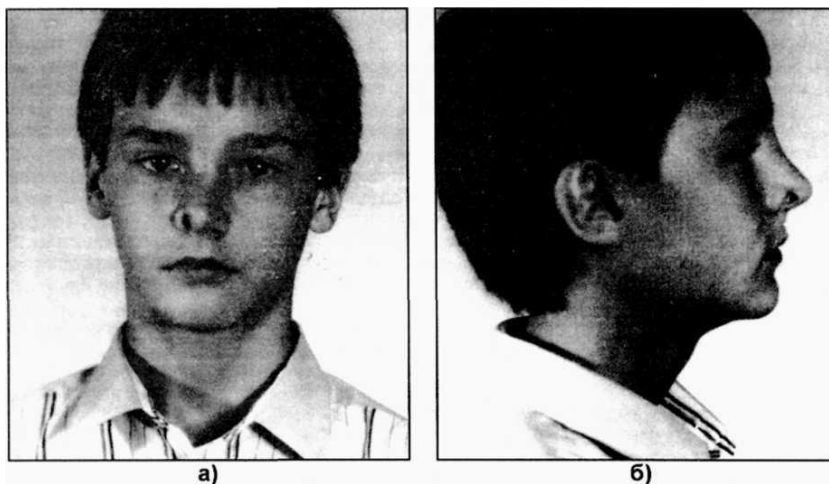2 degree-basal layer is amazed with formation of bubbles;

3 degree-necrosis of skin and subject soft of tissue.

4 degree-along with necrosis soft tissue necrotic the cartilage (bones of obverse skeleton at a freezing injury aren't damaged).

It is known that average temperature of air on the earth is below temperature of tissue of human body. It predetermines a constant heat from a human body. The heat it is counterbalanced by the warmed dwelling, a balanced diet, clothes and other. In the human body there are adaptive mechanism thermoregulation -it set of the physiological processes providing maintenance of optimum body temperature. At exhaustion or infringement of mechanisms an organism not in a condition to maintain normal temperature, especially in peripheral tissue, than and their primary defeat explained. Soft tissue of the person it is plentiful vascularized. Therefore freezing injuries of the person, as a rule happen on its acting parts (nose, ears, cheeks). There are contact freezing injuries of tongue, lips.

In the pathogenesis changes in tissue at freezing injury the leading role is played by infringements of their blood supply, the angiospasm, and then their thrombosis is observed in the beginning. Morphological changes in soft tissue. develop, basically, after their warming, during the jet period. In jet period Victims mark a pricking, burning, pain in the amazed site of the face and then comes their anesthesia (painful sensitivity disappears). The victims who are especially being in alcohol intoxication, can and not notice, when there comes a freezing injury.



Pic.6.13. Appearance of the child through year after the transferred freezing injury 4 degree. There is a defect of nose wing. a) front view; b) side view.

Clinic The most frequent and basic symptom of freezing injury of tissue in to reactive period is albication skin in cooling zone. Early symptom during the jet period is occurrence of hypostasis and skin reddening. In tissue develops serous or serous hemorrhagic inflammation. To define depth and weight of defeat during the first hours and even days after warming it is not obviously possible. About a damage rate of tissues it is possible to watch only presumably, within the next days the pathological phenomena can be aggravated.

At a **freezing injury of the first degree** after warming of tissue appear burning pain in area the itch, pricking are damaged tissue, develops paresthesia and hyperesthesia. (last lasts some days). It is observed hyperemia of skin, the hypostasis is expressed, painful sensitivity is lowered. The clinical semiology disappears in 4-8 days. Process comes to an end with a peeling of blankets of epidermis.

Freezing injury of the second degree it is characterized by destruction of epidermis (necrosis of blankets skin to sprout layer). Epidermis exfoliates, forming bubbles with serous or serous hemorrhagic contents. Bubbles appear within 2-3 days after defeat. At the bottom of bubbles fibrin in the form of touch which in regular intervals covers intact sprout layer of epidermis accumulates. Bubbles can independently burst, have thin surface covering them. Healing last 2-3 weeks, doesn't remain hems In the subsequent there is a hyper sensibility of skin (on this site) to cold.

Freezing injury of third degree- the skin loses painful sensitivity, remains cold and edematous, can accept cyanotic c oloring. All layers of skin and subject soft tissue perish. The big bubbles which are filled hemorrhagic by contents are formed. There are intoxication symptoms. On bubble place is formed the scab of dark color, which is torn away in 2-3 weeks later. The granulating wound is formed healing goes by formation of hem with regional epithelialization.

At a freezing injury of the fourth- the destruction not only soft tissue, but also a cartilage is observed.(wings of nose and auricles). Bones of the mouth - obverse skeleton at freezing injury aren't damaged. Freezing injury of fourth outcome is partial or full loss of body (nose and ear). Patients who have transferred freezing injury of fourth degree, further is necessary plastic elimination of defect.

Under the influence of low temperatures children can have a special kind of chronic dermatitis which perfrigeration -it is called a pathological condition of skin.

Topic № 7

DISEASES OF THE TEMPORO-MANDIBULAR JOINT

1. Arthritis

2. Arthrosis

3. Pain dysfunction of the temporo-mandibular joint

ARTHRITIS

Arthritis (synonym - osteoarthritis) represents inflammation of the TMJ. It is more common to young and middle aged people. Among the causes of arthritis may be included: local infection (periodontitis, gingivitis, stomatitis, otitis, tonsillitis, osteomyelitis of jaws, etc.), common infectious diseases (acute respiratory disease, influenza, pneumonia, dysentery, tuberculosis, syphilis, etc.), allergic diseases, traumatic exposure, etc. The para-allergic factors contribute to the emergence of inflammatory processes of TMJ (hypothermia, overheating, etc.), changes in the endocrine and nervous systems, the presence of foci of chronic infections (especially in the mouth), etc. The infection spreads into the joint by hematogenous and contact ways.

Depending on which factor is the cause of the disease, there can be distinguished the following types of diseases: **non-infectious** (exchange-dystrophic) **infectious** - specific (tuberculous, syphilitic, gonorrheal, actino-mycotic, etc.) and nonspecific (after otitis or osteomyelitis, rheumatism, and collagenosis etc.), **post-traumatic** (it occurs as a result of chronic microtrauma, acute trauma, surgical interventions on the jaw after tooth extraction due to the wide opening of the mouth, with a single joint overloading during the biting off of a large piece of apple or during the biting of solid food). Taking under consideration the clinical course of arthritis, **acute and chronic** arthritis can be distinguished. **Secondary arthritis** is an inflammation of the TMJ, which is the outcome of another illness or injury.

Acute arthritis is an acute onset, characterized by sharp pain in the TMJ, which can be intensified during the slightest movements of the lower jaw and radiating in the area of the face and of the head. The pain is constant, and only when the lower jaw alone, they are reduced. Immediately there is a sharp limit when opening the mouth and lower jaw motion is shifted to the affected joint. Pressuring on the chin, the pain in the affected joint is greatly enhanced, even when the mouth is closed. In front of the ear tragus swelling and infiltration appear in soft tissues, the skin may be congested. In serous arthritis in the joint cavity appears serous exudate, and in purulent arthritis appears a purulent one. The pronounced symptoms of intoxication (fever, weakness, malaise, increased erythrocyte sedimentation rate, etc.) depends on the activity of the inflammatory process and on the type of exudate. The duration of the disease is up to 2-3 months.

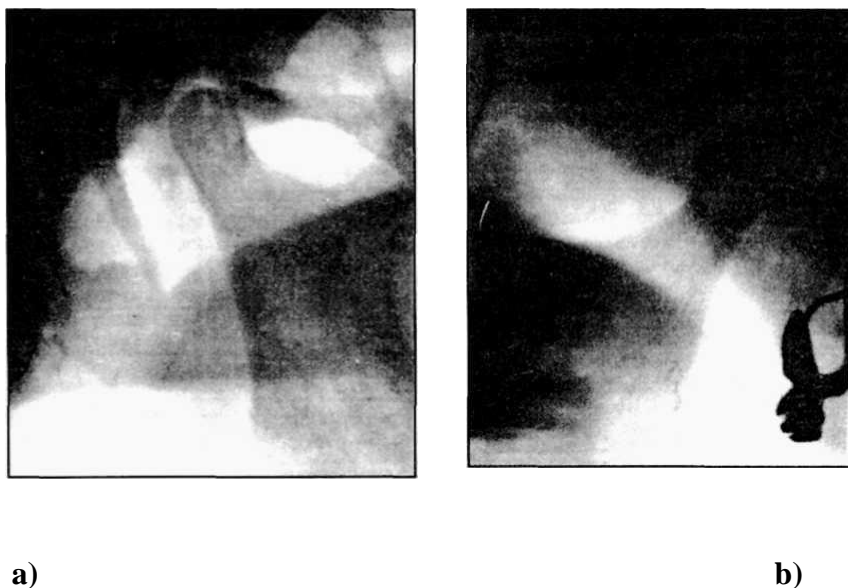
For rheumatoid arthritis bilateral involvement of TMJ is characterized, and when there is a con-stroke arthritis - a one-sided. In the childhood, the inflammation of the TMJ is caused by acute trauma (during the childbirth, fractures of the condylar process), the inflammatory process of transition from the inner or outer ear (otitis), osteomyelitis of jaw and temporal bone, in sepsis.

There are usually not radiographic changes, there can be seldom observed the expansion of joint space due to effusion (Pic.7.1).

Pathological changes in the joint occur by edema, hyperemia of the synovium, capsule and periarticular tissues, the appearance of turbid fluid (serous or purulent), bleeding into the joint cavity, phlebitis and arteritis, the nerves are compressed, and there is a symptom of pain.

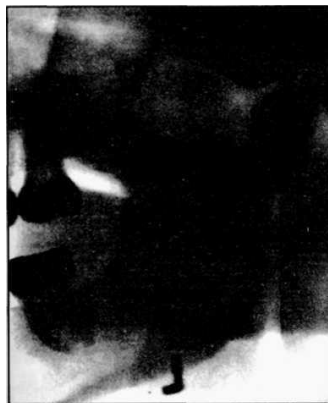The acute arthritis of the TMJ should be differentiated from the following diseases: osteoarthritis, painful TMJ dysfunction, acute otitis, fractured condylar process of the mandible, a limited branch of osteomyelitis of the mandible, osteomyelitis of the upper jaw of teeth, impeded eruption of wisdom teeth and their complications, myositis, an inflammatory contracture of masticatory muscles, trigeminal neuralgia, ear node ganglionitis

Chronic arthritis is the duration of the course from several months to several years. It is characterized by moderately severe pain in the TMJ, which are often triggered by hypothermia, after a long conversation during the meal (solid). There is stiffness in the joints in the morning and late in the day. Stiffness in the joint when chewing or talking, mouth opening restriction is observed, mainly in the period of exacerbation. The subjective symptoms may include: pain near the ear tragus, paresthesia or hyperesthesia of the skin of this region, the crunch in the joint. When there is an exacerbation the clinical symptoms acquires symptoms of acute arthritis.



Pic.7.1. Radiographs of the TMJ of a healthy person (a) and of the patient with acute arthritis (b). There are not bone changes.

Pathological changes are formed after the acute stage of the disease, the scars wrinkle the joint capsule and deform the articular gap. There are areas of fibers, and occasionally necrosis of cartilage. Cartilage defects are filled with granulation tissue, which turns into a scar. There are pockets of osteoporosis, and in the future the deformation of the articular surfaces.



Pic. 7.2. Radiographs of the TMJ of the patient with chronic arthritis. There is a deformation of the joint space (narrowing in the back of its localization).

The X-ray symptoms of chronic arthritis vary. Restriction sites are found (usually) or extension (rare) of joint space, the centers of osteoporosis and bone destruction of the joint elements of the TMJ (Pic. 7.2). X-ray detectable joint narrowing space indicates the degree of damage to the cartilage. In some cases (after purulent fusion of cartilage), the joint space narrows evenly, and then ceases to differentiate. A fibrous, and then bony ankylosis develops.

Secondary TMJ arthritis that occur the children after otitis, are radiologically characterized by destructive changes in the articular head, irregular narrowing of joint space, followed by fibrous and bony ankylosis. Arthritis developed on the basis of osteomyelitis of the mandible leads to a rapidly progressive destruction of the articular head and neck of the mandible. First, there are pockets of osteolysis and necrosis, and later sequestrars are formed. Cartilaginous elements of the joint die, and the naked bone of the glenoid cavity and the head of the lower jaw grow together, causing stiffness in the joint. When there is a *fibrous ankylosis* of the joint space, the subtle is flattened radiographically, the articular head and neck become thicker. When a *bony ankylosis* is noticed radiographically, there can be observed the complete disappearance of the joint space and bony fusion of the head of the mandible with the glenoid cavity of the temporal bone forming a single bone conglomerate (which may include the zygomatic arch), there is a thickening and shortening of the neck of the mandible (in case of the growth zone damage of the mandible). This leads to a deformation of the face as a result of underdevelopment of the mandible. In case of a *destructive osteomyelitis and high fracture of muscular process* may be functionally deficient compound bone at the site of the pathological center, which serves as a replacement. This joint is called a pathological neo-arthritis.

Outcome of arthritis in children may be **ankylosis** - the lack of mobility in the joints due to inflammation, degenerative process or injury. The ankylosis may be extra-articular - due to the extra-articular bone bridge between the bones forming the joint; intra-articular due to the mating joint surfaces. **Intra-articular ankylosis** may be: fibrous - the presence of cicatricial adhesions between the mating joint surfaces, bony - caused by the bone fusion of the articular surfaces of the (radiographical joint gap is absent).

Ankylosis must be distinguished from **contracture** - a persistent limitation of motion in the joint, which occurs as a result of changes occurring outside it. There are contractures: arthritic - due to changes in the joint capsule or ligaments, pain contracture - reflex contraction that occurs with pain in the joint motion; myogenetic - due to injury, inflammation, degenerative process in the muscles or the immobilization of the

mandible (jaw fracture fixation); neurogenic - in violation of the nervous regulation; cicatrical - due to gross changes in the scar tissue, encircling the joint.

The treatment of arthritis depends on the shape of its clinical course and the reasons that caused the development of the disease. In the treatment of arthritis of any etiology must be first obviously turned a rest in the joint, limiting the function of the lower jaw. The patient was imposed a chin - a gauze bandage or parietal head hat with elastic chin thrust to the sling, and in the same time the rubber gasket with a thickness of 5-10 mm between the large molars (to prevent ankylosis). Surgical intervention (capsulotomy) is shown at the presence of purulent exudate in the joint cavity. It is necessary to make an external incision along the lower edge of the zygomatic arch and a subsequent drainage of purulent focus.

In the acute stage of disease, or aggravated stage antimicrobial, anti-inflammatory are prescribed (indomethacin, orthofen, naproxen, piroxicam, and others), painkillers, antihistamines (hyposensitizing), sedatives. There are prescribed physiotherapy, hot compress, UHF-therapy, electrophoresis with anesthetics and other procedures.

We recommend that you be wary of putting into the joint cavity of drugs, because there can be frequently observed complications associated with their introduction.

After removal of acute inflammation is conducted orthopedic treatment (if indicated). In the chronic stage of the disease among the remedial measures the advantage goes to physiotherapy: electrophoresis 3% potassium iodide; medical compression with bile, bischofite, ultrasound, phonophoresis with hydrocortisone, etc.

If the inflammation of the temporomandibular joint is caused by rheumatoid arthritis, tuberculosis, syphilis, actinomycosis, or other diseases, it should be treated by a doctor - a specialist.

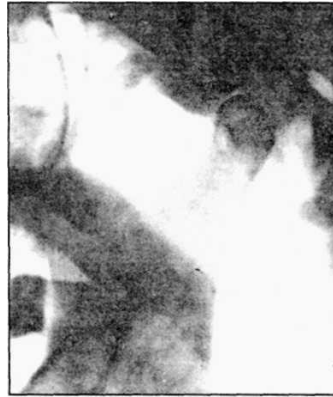ARTHROSIS

Osteoarthritis (*synonym - osteoarthritis*) is a dystrophic disease of the TMJ, which is based on degeneration of articular cartilage, which leads to its thinning and its turning into fibers, exposure of underlying bone and bone growths.

The degenerative processes in the joint develop as a result of an imbalance between the load on the TMJ and physiological endurance of its tissues. Normally the load, which develops chewing muscles evenly is distributed on the two joints, all teeth and periodontium. Therefore, overloading of the joints cannot occur. **In case of the loosening of teeth, especially molars and premolars, there has been a sharp increase in the load on the articular surface, and the head of the mandible is moving deeper into the joint hole.** There is an overload of TMJ. It is more common in elderly and senile age due to tooth loss, misuse or lack of dental prosthetic dentures, involutive changes in the tissues. **Arthritis occur patients with dentition defects, breach of interdigitation (pathological occlusion), systemic lupus erythematosus, metabolic disorders and diseases that lead to the emergence of pathological osteoporosis.**

Osteoarthritis may be primary (with the loss of teeth, etc.) and secondary (the outcome of certain diseases or injuries). Depending on the clinical picture of arthritis, there are distinguished: sclerosing (there is sclerosis of the cortical bone of the articular surfaces of the plates) and deforming (characterized by severe destructive and (or) hyperplastic changes of the bone elements of the joint). In the case of the deforming arthrosis may appear an abnormal bony growths on the surface of the bone - osteophytes.

The clinical symptoms. The disease is chronic (for six months to several years). The patient complaints boil down to a dull aching pain in the TMJ, the pain intensified during the meal (especially solid), after a long conversation, or hypothermia, due to emotional stress. The mouth opening is limited and jaw shifts to one side. There is stiffness, joint stiffness in the morning, and within days it seems to be "developed" There is a crunch in the TMJ, some hearing loss, a feeling of fullness in the ear. Radiographs of the TMJ is characteristic (Pic.7.3.-7.4.)

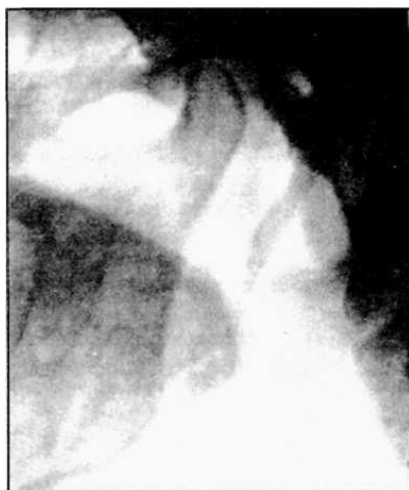

Pic.7.3. Radiographs of the TMJ of patients with deforming arthrosis. There is sclerosis, cortical bone and its articular head deformity and destruction (expansion) in the mandibular fossa of the temporal bone.

The immediate cause of the disease often is arthritis that develops as a result of joint trauma or osteomyelitis of the mandible condyle. V.I. Kutsevlyak and E.N. Ryabokon (1994) studied in detail and described **the features of the clinical symptoms of the secondary deforming arthrosis of TMJ in the childhood and adolescence.**

According to their observations in the external examination at patients with unilateral disease is marked a facial asymmetry, reducing the height of the lower zone of the face (a shortening of the body and branches of the lower jaw). The front chin of the lower jaw is shifted to the side of underdevelopment. The affected party have rounded contours, as it is indicated an excess of soft tissue and creates the impression of a healthy one. The healthy side of the lower zone of the face is sunken and flattened due to the apparent stretching of the skin between the angle of the mandible and chin, shifted to the affected side. The mouth is oblique. The angle of the mouth on the side of underdevelopment is shifted downward. The naso-labial fold of the undeveloped part is short, deep.

When there is a disease of two temporo-mandibular joints, the both halves of the lower jaw are lagging behind in the development, the chin is displaced posteriorly and is installed a characteristic profile of a person "bird-like face." The upper jaw and nose sharply issued in advance.



Pic. 7.4. The radiographs of the TMJ of the patient with a deforming arthrosis. There is a deformation of the head of the mandible, a flattening of the articular tubercle.

There is a concomitant asymmetric deformation of the jaw (by V.I. Kutsevlyak and E.N. Ryabokon, 1994):

- lower asymmetric micrognathia:
- a secondary deformation of the upper jaw, which is manifested in the asymmetric reduction of its height on the affected side, the restriction (more on the healthy side due to the displacement of the mandible to the affected side), the protrusion (pushing, protrusion, extension) of the front;
- deformation of the occlusal plane;
- distal occlusion;
- lack of contact of incisors (sagittal gap reaches an average of 10-15 mm);
- there is often overlap of the cutting depth;
- traumatic deep bite, open bite in the less anterior;
- deformation of the shape of tooth-alveolar arcs of the upper and lower jaws, the lingual slope of the alveolar bone and teeth on the affected side of the lower jaw;
- the narrowing of the dental arches in lateral sections, the lengthening of the anterior upper dentition, the shortening of the front of the lower dentition, its flattening;
- frequent protrusion of incisors of both jaws, the close position of the front teeth of lower jaw;
- there is sometimes a retention of the lower canine teeth on the affected side, vestibular eruption of the canines;
- the displacement of the mandible in the affected side.

The lateral movement in the joint stops the first, and then become limited vertical movement and forward movement. The reduced range of motion in the joint takes place slowly, over the years and ends with complete immobility of the mandible. Underdevelopment and the immobility of the lower jaw create the conditions for the tongue and epiglottis, which leads to disruption of external respiration and pulmonary ventilation. These abnormalities are especially pronounced in the relaxation of muscles during the sleep. In the dream, the children snore heavily. Children cannot sleep lying on their back and sleep half-sitting.

Radiographic features of the secondary deforming arthrosis were studied by N.N. Kasparova steam and her colleagues (1981) and presented in a 4-radiological stages of the disease:

- Ist stage - *osteoarthritis (arthritis)*, is the beginning of the disease. As a result of inflammation, the cartilage dies. This period remains unrecognized because it is poorly understood.
- IInd stage - *the destruction of the articular head and the initial events of the repairing*. On the X-ray joint the space is seen in the form of irregularly narrowed strip. Articular process loses uniform structural pattern, the head is destroyed, we see a flattening of the head. The initial manifestation of boundary growths are identified mainly of the cutting lower-jaw edge as separate bony outgrowths. The contours of mandibular fossa retain terrain, are not changed.
- IIIrd stage - *strong reparations*. X-rays is determined by: joint space in the form of an increasingly close to a straight line, sometimes dramatically narrowed. The articular process is dramatically flattened and deformed; the transverse dimensions are larger than the glenoid fossa. The sclerosis of bone structures is revealed. At this stage there is a deformation of the temporal bone in the form of reducing the depth of mandibular fossa and articular tubercle smooth, incongruent articular surfaces.
- IVth stage - *complete loss of congruence mating surfaces*. The joint gap completely loses bends and approaches to a straight line that can be traced throughout. The articular process is broad and short. The boundaries of the head are not defined. The boundaries of mandibular fossa and articular process are smoothed out, approaching to a straight line. The zone of the thick bone is determined and the marginal bone growths.

The diagnosis is based on data from medical history, clinical symptoms and radiologic studies.

The differential diagnosis of osteoarthritis should be carried out with the pain of TMJ dysfunction, with fibrous and bony ankylosis, contracture of the lower jaw, some congenital diseases. Among the latter, you should know about syndromes involving mandibular bone dysplasia:

- The Robin syndrome is characterized by hypoplasia of the lower jaw, cleft hard and soft palate, the tongue;
- Syndrome I and II of branchial arcs represents a hypoplasia of one half of the upper and lower jaws, the zygomatic complex, transverse facial cleft, breach of the outer and inner ear, hypoplasia of the pinna and ear pendants come trestle;
- Goldenhar syndrome (vertebral dysplasia) - is characterized by hypoplasia of the lower jaw, eye abnormalities and malformations of the spine.

It must be remembered that the **youthful TMJ dysfunction** (youth arthropathy, juvenile deforming arthrosis, etc.) occurs more often in the 16-18 years old. During the adolescence, the bone growth outstrips the growth of the skull and the functional adaptation of muscle and ligaments. As a result of the intensive growth of the lower jaw the ligaments TMJ reaches a state of hyperinflation. First, this is compensated by elastic ligaments, and then they lose their tone and the capsule is too stretched. In the joint, it is possible to do large scale motions (when opening the mouth) and the head of the lower jaw may extend beyond the boundaries of the joint, so in the state of subluxation and dislocation (distension luxation - with hyperextension joint capsule). There is an increased load on the joints, which leads to the development of acute and chronic arthritis, and in some cases it causes deforming arthrosis. The disease lasts for many years.

The treatment of osteoarthritis consists in restoring proper bite, rational prosthetics, physiotherapy appointment: electrophoresis and phonophoresis with anesthetics, potassium iodide, hydrocortisone (prednisolone). In case of limiting the mobility of the mandible and its progressive deformation in patients with secondary deforming arthrosis a surgical treatment is prescribed (bone grafting).

PAIN DYSFUNCTION OF THE TEMPOROMANDIBULAR JOINT

The pain TMJ dysfunction syndrome (TMJ pain) has synonyms: Costen syndrome, TMJ pain dysfunction syndrome, dysfunctional syndrome myofascial pain, TMJ dysfunction, cranio-mandibular dysfunction, dysfunction of the lower jaw, muscular - articular dysfunction, TMJ, etc.

J. Costen (1934) described the syndrome, which was watched to edentulous patients and those with low bite. The syndrome is characterized by the following: dull pain in the joint, headache, dizziness, pain in the cervical spine, neck and behind the ear, increasing at the end of the day, clacking in the joint during a meal, hearing loss, tinnitus, burning in throat and nose. The above symptom complex was subsequently named the syndrome Costa. This syndrome later added several other symptoms: paresthesia, dry mouth, a feeling of pressure in the ears, ear pain, etc.

J. Costen (1936) believed that the symptoms associated with hearing loss, tinnitus, and others appear because of the pressure head of the mandible to the auditory tube. Reduced occlusion leads to a pressure head of the mandible on the set of glenoid fossa, which separates the joint cavity from the dura mater, and therefore there is a dull pain in the spine, and pain in the tongue and the temporal region is observed as a result of pressure head on ear-temporal nerve and the tympanic chord.

Thus the concept of occlusion of TMJ pain arose. However, it has some unexplained part. Why TMJ dysfunction appears in individuals without changing the bite (occlusion without breaking)?

In the future, a new theory appears - the effect of psychological stress factors. A special attention is paid to emotional factors, stress, a result of this state of stress arises from clenching the teeth, causing muscle spasm and pain. It was found that 53% of patients have a neurogenic pain dysfunction and psychiatric disorders (Fainman C. et al., 1984).

Bruxism (teeth grinding during sleep), and other para-functional habit is seen as a cause of functional impairment, which manifest themselves in the form of muscle pain, cramps and TMJ (Moss R.A., Garrett J.C., 1984; Ravone B.W. et al., 1985). In addition to psychological factors, hormonal changes cause the improvement of muscle tone (menopause), thyroid disease, and internal organs (liver) rheumatic disease.

Abnormalities in the dental system are the starting point in the development of TMJ pain. A. Mirza explains the pathogenesis of this syndrome as follows. In cases when, during closing of the individual teeth of dentition, or parts of their occlusal surfaces are in contact before the other (*premature contacts, extra-contacts*) are obstacles to closing the other teeth. This can lead to displacement of the mandible in a forced situation, when multiple contacts are achieved at the cost of breach of co-ordinated function of masticatory muscles and the change in the position of the articular heads. This leads to disruption of normal bilateral function of the masticatory muscles and TMJ components and clinically pain dysfunction. Defectively manufactured denture with the unreconciled occlusal contacts, cause pain and discomfort while using them. The function of masticatory muscles changes, chewing is reconstructed, which leads to microtraumas of articular elements and their trophic disturbance. Clinical studies conducted by A.I. Mirza (1993) proved that the ongoing changes in the relative position of the articular heads, holes is redistributed the functional load to certain areas of articulation. In areas where the load increased, there is compression of soft tissues in other areas where is a stretch, a distraction. As a result, there are cracks, perforation, rupture disc and articular cartilage, ligament sprain joints, dislocation of the disc, trophic changes in the joint

In the absence of timely etiopathogenetic treatment, the pathological process of soft tissue changes in the articular surface.

The location and severity of destructive changes in the TMJ depends on the spasm of the masticatory muscles and the direction of displacement of the articular heads. Since the loss of posterior teeth on the left, the lower jaw is shifted predominantly to the right. In this case the left articular head (non-working side) moves forward, downward and inward, there is a microtrauma of the anterior joint, disc compression, stretching the capsule and ligaments of the joint, and the top flattened slope of the articular tubercle. The right articular head (working side) while shifts upwards, backwards and outwards, there is a microtrauma rear of the upper and outer joints, flattened articular head. In case of losing the right posterior it can be developed a similar clinical picture, but on the other side (A.I. Mirza. 1993).

The clinical symptoms were similar to that in arthritis and arthrosis. Patients complain of a dull, nagging headache, and TMJ. There is pain and tenderness on palpation of the parotid or the external auditory canal, as well as opening and closing the mouth. There can be irradiation of pain in the temporal and infraorbital area, and in some cases, neck and spine. They can feel clicking and crepitus in the TMJ, the presence of painful and spastic sites in the masticatory muscles, muscle pain increases when you open your mouth. Palpation of the TMJ is a painless, the scale movements of the mandible is enlarged.

It is proved that the cracking in the joints is a consequence of anterior displacement of the meniscus (Tallents R.H .et. al., 1985; Westesson P.L. et. al., 1985). When you open your mouth, the articular head in contacts with the rear edge of the meniscus and then jumps to the center position of its concave zone, producing a click. In the reverse movement of the condyle, jerky jumps over the rear edge of the meniscus, causing the joint sound. It is noted that the clicking sound when you open your mouth occurs at a later time than at closing.

It is characteristic to TMJ the pain is the deviation of the mandible to one side when opening the mouth, S-shaped motion. V.N. Banuh (1986) proposes to allocate two clinical forms of the disease: latent and active. For the latter form is characterized pain and symptoms of acoustic (noise, crackling, clicking).

Radiographic studies of TMJ indicate the absence bone changes. It is observed an asymmetry in the location of the articular heads and joint gaps.

Through the differential diagnosis of TMJ pain with arthritis or osteoarthritis is recommend using a table (Table 23.3.1), proposed by A.I. Mirza (1993).

**Differential diagnosis of the most common diseases of the temporo-mandibular joints (AI
Mirza, 1993)**

№	Symptoms	Pain dysfuncti on	Arthritis		Osteoarthri tis
			harp	hronic	
1	2	3	4	5	6
Patients' complaints:					
1	Headache (constant, tight, aching)	+			++
2	Dull, aching pain of a TMJ	++			++
3	Sharp pain in the TMJ joint	+	++		
4	Acute onset of disease		++		
5	Chronic diseases (from 6 months to several years)	+		+	++
6	The pain is worse:				
	6.1 - when moving the lower jaw;	+	++		
	6.2 - while trying to open the mouth wide;	+	++		+
	6.3 - during a meal, especially hard;	+	++	+	++
	6.4 - due to emotional stress;	++			++
	6.5 - due to hypothermia;	+	++	++	++
	6.6 - after a long conversation.	+	++	++	++
7	Mouth opening is limited due to pain (10 mm)		++		
8	Inability to movements of the lower jaw		++		
9	Irradiation of the pain	+	++		
10	Clicking in the temporo- mandibular joint	++			
11	Crunch in the temporo- mandibular joint			+	++
12	Hearing loss	+			++

		++			
13	The feeling of fullness in the ear (tinnitus)	+			+
14	Eye muscle twitching	++			
15	Gnashing and compression of teeth during the dream	+			
16	Feeling details jaw after sleep	+			
17	Tightness and pain in the masticatory muscles	++			++
18	Burning sensation in the mouth	++			
19	Tight mobility in the joint at the end of the day	+		++	
20	Tight mobility, stiffness in the joints in the morning	+		+	++
21	During the day, the lower jaw is "developed"	+			++
22	Paresthesia of the oral mucosa				++
+++ - most often; ++ - less often; + - rarely					

The differential diagnosis should be done with trigeminal neuralgia and autonomic ganglia maxillo - facial area. All this will be discussed in detail in the next chapter of this manual.

The syndrome of the styloid process (Eagle syndrome) occurs at its excessive extension. It is characterized by pain on swallowing, and in the root of the tongue (while driving), irradiating the region of the ear, pain when turning head, headaches, dizziness (due to the pressure of styloid process in the carotid artery, especially when moving the head). Palpation of the lower anterior palatal arch and the floor of the mouth is determined by an elongated styloid process (in the norm of its size of about 25 mm). On the radiograph enlarged styloid process is visible and the end of his department is projected in the angle of the mandible (Tab. 7.2.).

Tab. 7.2.

The syndrome of the styloid process (Eagle syndrome)

№	Symptoms	Pain dysfunction	Arthritis		Osteoarthritis
			harp	hronic	
1	2	3			6
Clinical symptoms:					
1	Click	+			
		++			

2	Crunch				+++
3	Crepitus	++	+		
4	Limited mouth opening	+	+	++	+
5	Opening the mouth the lower jaw is shifted aside	++	+	+	+++
6	Opening the mouth, the lower jaw makes S-shaped motion	++	+		
7	The pain increases sharply in all the movements of the mandible			++	
8	The asymmetry of the face due to swelling			++	
9	Swelling in front of the ear tragus			++	
10	The presence of painful and spastic sites in the muscle	++	+		
11	No signs of inflammation in the TMJ	++	+		+
12	The presence of signs of inflammation of the TMJ			++	
13	On palpation of the external auditory canal				
	13.1 - the ear canal is free	++	+		+++
	13.2 - ear canal is narrowed, pain			++	+
	13.3 - the front wall is painless	++	+		
	13.4 - the front wall is painful			++	+
14	Palpation of the temporo-mandibular joint is painless	++	+		++
15	Pain in the joints increases pressuring on the chin			++	+
16	Pain when pressing on the tragus ear			++	+
17	Limited range of motion of the mandible			++	+
18	Increased range of motion of the mandible	+	+		+++
19	Increased body				

	temperature		++		
X-rays studies:					
1	TMJ bone structures are not changed	+	++	+	
2	The asymmetry of the location of the articular heads	+	++	+	
3	The asymmetry of the articular slots	+	++	+	
4	Joint space narrowing				++
5	Sclerosis of the cortical bone of the articular head and articular tubercle				+++
6	The presence of ecsofits on the articular surfaces				+++
7	The deformation of the head of the mandible				+++
8	Flattening of the articular tubercle				+++
9	The shortening of the cervix condyle				+++
+++ - most often; ++ - less often; +- rarely					

The treatment of painful TMJ complex. The first step is to normalize the occlusion. A. Mirza (1993) recommends that in order to eliminate individual sections of occlusive tooth surfaces that prevent multiple contacts of the teeth, apply selective grinding of the teeth. In this case, the following complications can appear: reduction of interalveolar height (the height of the central occlusion), hyperesthesia of hard dental tissues, excessive stress on the periodontium, removal from the contact of some teeth and periodontal overload of other teeth. **Therefore, for the correct application of this method takes into account the correction of occlusive basis of biomechanics masticatory apparatus, and can be followed certain rules.** Thus the tops of the reference mounds (upper palatal and lower buccal) are not polished because of the fact that they provide the stability of the central occlusion keeping the occlusal height.

Protective mounds (upper buccal and lower lingual) are preserved, since the first protect the mucous membrane of the chin. The second – protect the tongue mucosa from its getting between the teeth. The mounds rocks are polished that disturb the dynamic occlusion, the sections of the teeth that are not erased, the fissures deepen, the sharp edges are smoothed. The teeth are not removed from the contact in the central occlusion. In order to avoid the excessive teeth polishing, first of all it is advisable to draw up a plan of the polishing in the mouth than the teeth can be polished.

Bibliography:

- 1) Băcuț G. *Urgențele medico-chirurgicale*. Editura Medicală Universitară. „Iuliu Hațieganu” – Cluj-Napoca, 2002.
- 2) Burlibașa C. *Chirurgie orală și maxilofacială*. Editura Medicina – București: Editura medicală, 2003.
- 3) Ghicavîi V. *Farmacoterapia afecțiunilor stomatologice*. Ghid. V. Ghicavîi, S.Sârbu, D.Șerbatiuc, Ed.a 2-a revăz. Și compl.- Chișinău, 2002.
- 4) Безрукова В.М., Робустова Т.Г. Руководство по хирургической стоматологии и челюстно-лицевой хирургии, том 1, Москва, 2000.
- 5) Робустова Т.Г. Хирургическая стоматология, Издание второе, переработанное и дополненное, Москва, 2000.
- 6) Тимофеев А.А. Руководство по челюстно-лицевой хирургии и хирургической стоматологии. Киев, 2002.
- 7) Шаргородский А. Г. Клиника, диагностика, лечение и профилактика воспалительных заболеваний лица и шеи. Москва, 2002.

Content

Introduction.....	2
Topic № 1 Gunshot wounds of the maxillofacial area.....	3
Topic № 2 Particularities of the gunshot fractures of the middle facial area.....	9
Topic № 3 Combined injures	14
Topic № 4 Nutrition and care of wounded into the maxillo-facial area.....	18
Topic № 5 Complications of jaw fractures.....	20
Topic № 6 Thermal defeats.....	31
Topic № 7 Diseases of the temporo-mandibular joint.....	41